Leishmaniosi canina:
aspetti clinici e terapeutici

Francesco Dondi
DVM PhD Professore Associato
Ospedale Veterinario Universitario
Dipartimento di Scienze Mediche Veterinarie
Alma Mater Studiorum - Università di Bologna

Consulente MYLAV
Nefrologia e urologia

Leishmaniosi - Diagnosi

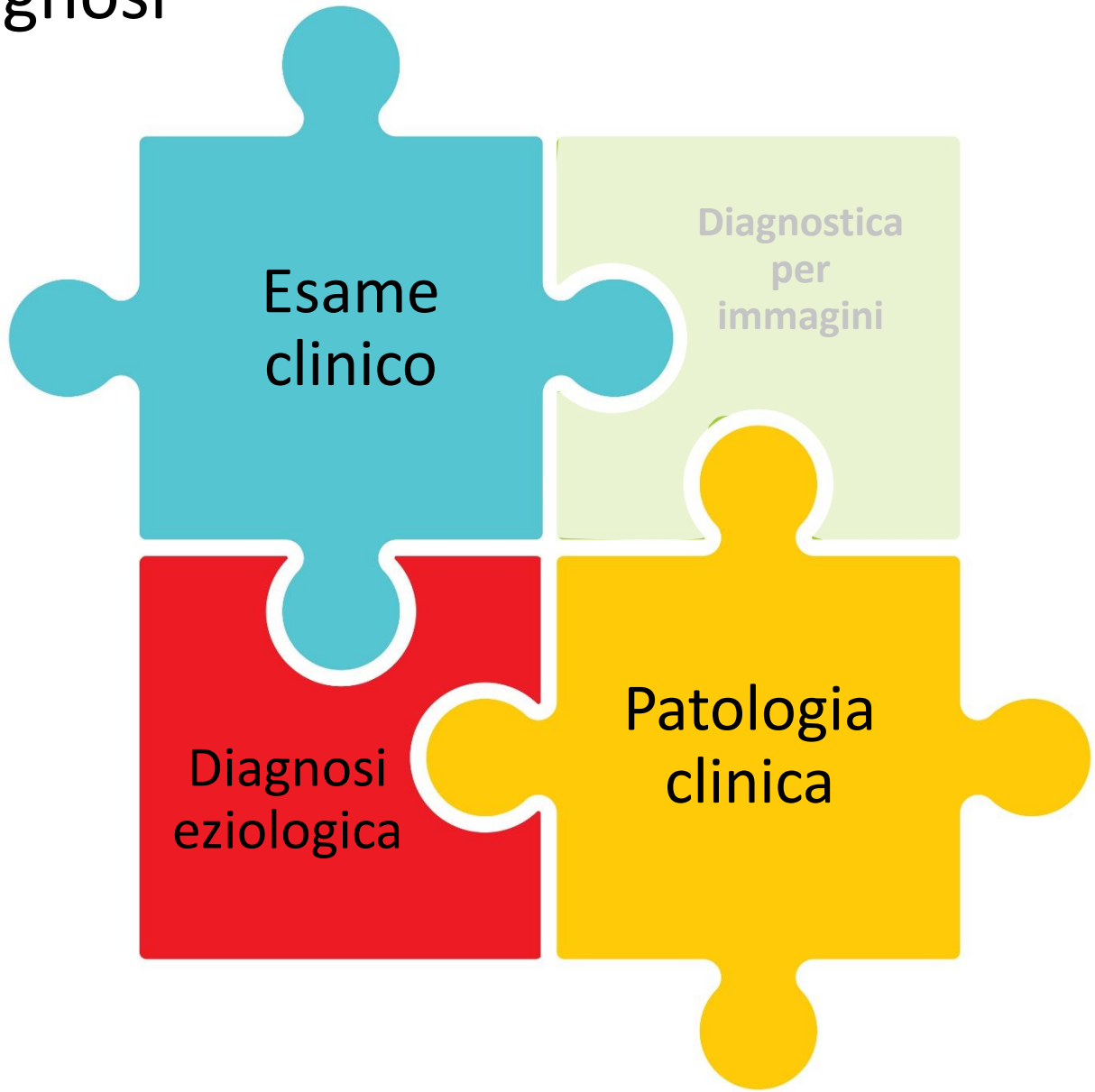

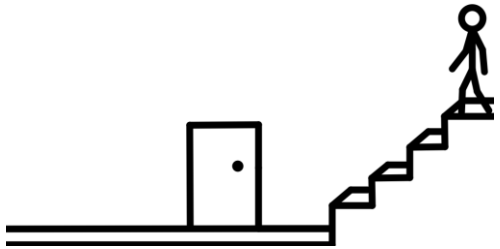

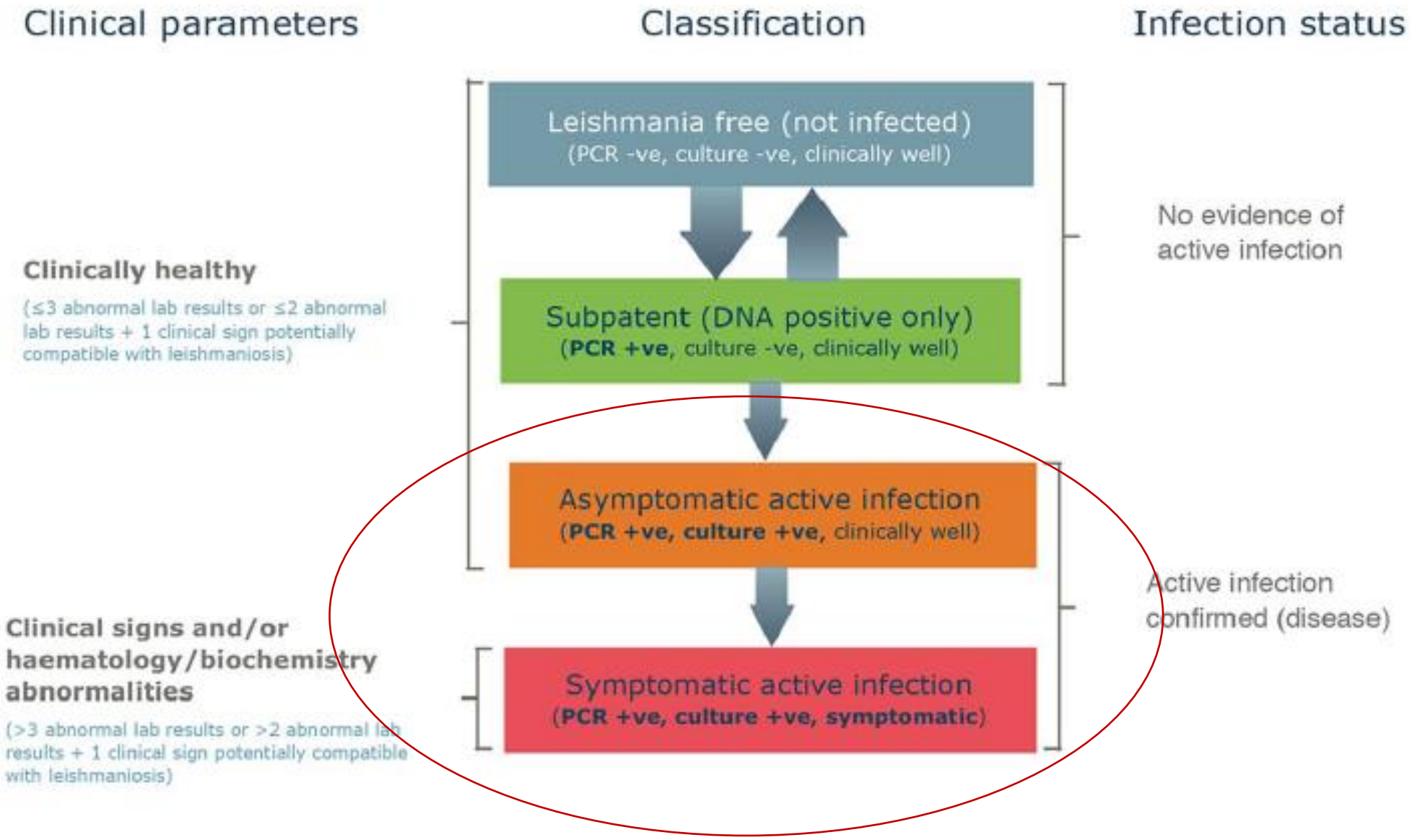

Oliva G., Nieto J., Manzillo V. F., *et al.*(2014). A randomised, double-blind, controlled efficacy trial of the LiESP/QA-21 vaccine in naive dogs exposed to two leishmania infantum transmission seasons. *PLoS Negl Trop Dis*, *8*(10), e3213.

LEISHMANIOSI CANINA
SEGNI CLINICI

Tabella 1. Segni clinici e alterazioni clinico-patologiche riscontrabili nella CanL causata da *L. infantum*.

SEGNI CLINICI

Sistemici

- Aumento di volume dei linfonodi esplorabili
- Perdita di peso
- Diminuzione o aumento dell'appetito
- Letargia
- Pallore delle mucose
- Splenomegalia
- Poliuria e polidipsia
- Febbre
- Vomito
- Diarrea

Cutanei

- Dermatite esfoliativa non pruriginosa con o senza alopecia
- Dermatite erosivo-ulcerativa
- Dermatite nodulare
- Dermatite papulosa
- Dermatite pustolosa
- Onicogrifosi

Oculari

- Blefarite (esfoliativa, ulcerativa o nodulare) e congiuntivite (nodulare)
- Cheratocongiuntivite, comune o secca
- Uveite anteriore
- Endoftalmite

Altri

- Lesioni mucocutanee e mucosali ulcerative o nodulari (orali, genitali e nasali)
- Epistassi
- Zoppia (poliartrite erosiva o non–erosiva, osteomielite, polimiosite)
- Miosite atrofica dei muscoli masticatori
- Disordini vascolari (vasculite sistemica, tromboembolismo arterioso)
- Disordini neurologici

ALTERAZIONI DI LABORATORIO

CBC*/Emostasi

- Anemia arigenerativa lieve o moderata
- Leucocitosi o leucopenia: linfopenia, neutrofilia, neutropenia
- Trombocitopatia
- Trombocitopenia
- Alterazione dell'emostasi secondaria e fibrinolisi

Profilo ematobiochimico ed elettroforesi delle proteine sieriche

- Iperproteinemia
- Iperglobulinemia (gammaglobulinemia e/o betaglobulinemia policlonale)
- Ipoalbuminemia
- Riduzione del rapporto albumina/globuline
- Iperazotemia renale
- Aumento degli enzimi epatici
- Proteinuria

* CBC: complete blood count (esame emocromocitometrico)

LeishVet

"Segni clinici" di leishmaniosi

↓

segni clinici
e/o
alterazioni di laboratorio !

Leishmaniosi e danno d'organo

- Presenza diretta del parassita
- Flogosi granulomatosa
- Immunocomplessi
- Autoanticorpi
- Complicazioni



Leishmaniosi e Immunocomplessi

Ricorda:

i cani che hanno forme cliniche caratterizzate da lesioni riferibili a immunocomplessi hanno prognosi peggiore !

STADIO III Malattia grave	Titoli anticorpali da medi a elevati	Cani che, oltre ai segni clinici elencati negli Stadi I e II, possono presentare segni causati da lesioni da immuno-compessi (e.g. uveite e glomerulonefrite)	Alterazioni clinico-patologiche elencate nello Stadio II Insufficienza renale cronica (IRC) in stadio IRIS I con UPC= 1-5 o stadio II (creatinina 1.4-2 mg/dl)***	Allopurinolo + antimoniato di meglumina o miltefosina Secondo le linee guida IRIS per IRC***	Da riservata a infausta

LeishVet

Immunocomplessi e danno d'organo

Distretti più sensibili al deposito di complessi immuni:

Vasi	→ vasculite
Rene	→ glomerulonefrite
Articolazioni	→ poliartrite
Occhio	→ uveite
Muscolo/cuore	→ miosite, miocardite, versamento pericardico
Meningi	→ meningoencefalite … ?
Ossa	→ osteo-periostiti e osteolisi …. ?

Leishmaniosi – Segnalamento – età

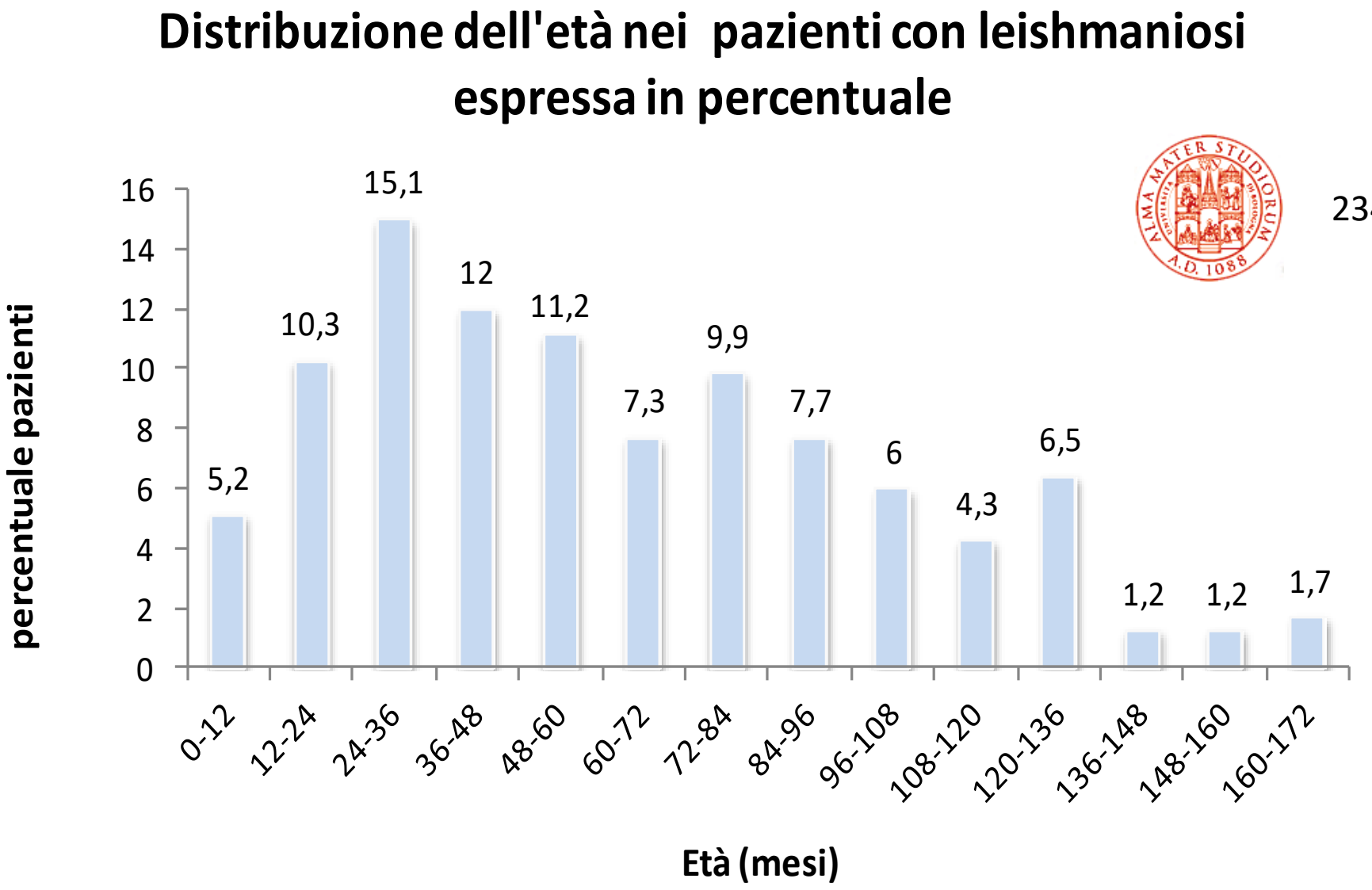

234 casi *unibo*

Leishmaniosi - Segnalamento

Razza: tutte le razze
Boxer e Pastore tedesco sono più rappresentate in letteratura

Sesso: alcuni studi riportano una prevalenza maggiore nei cani sesso maschile

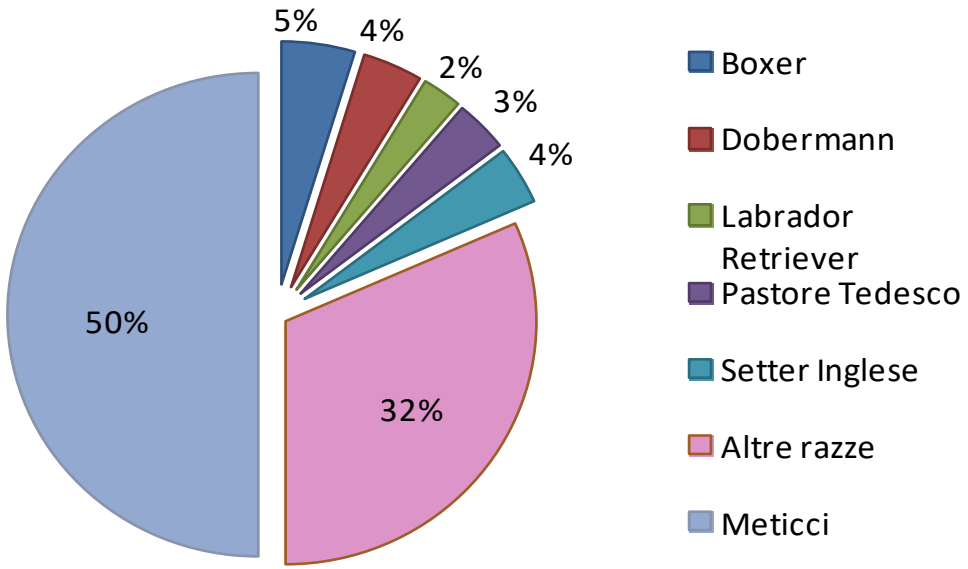

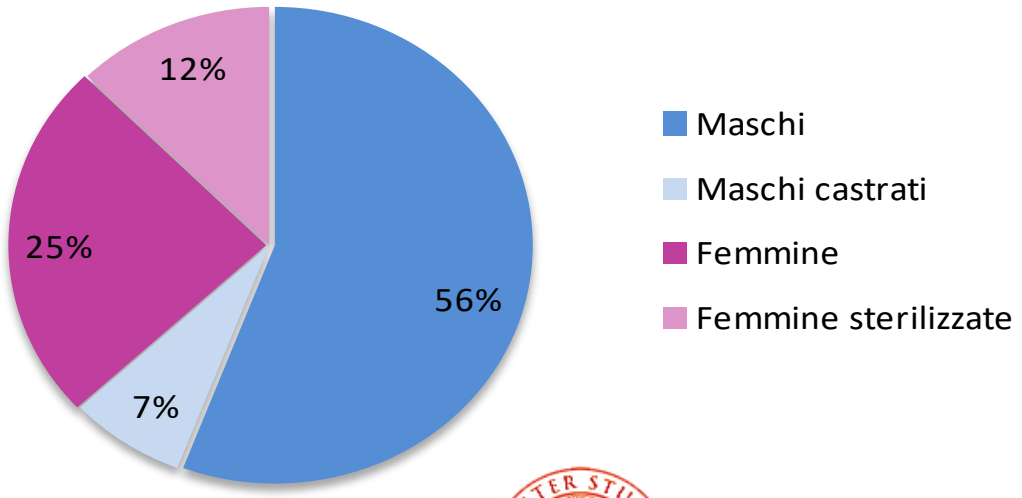

234 casi *unibo*

Leishmaniosi – Anamnesi !

Anamnesi ambientale è ancora fondamentale !

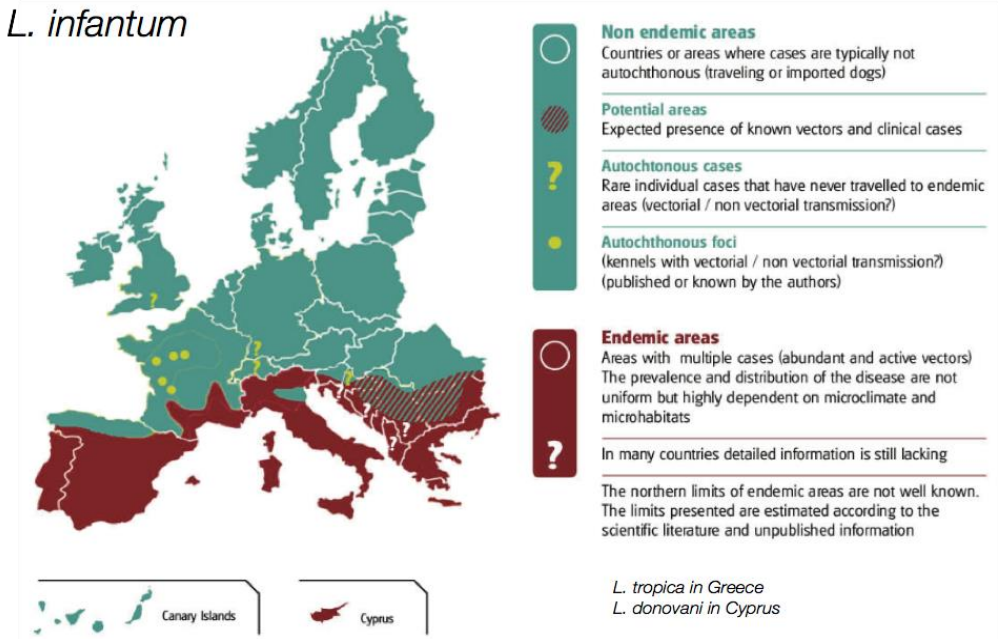

Figure 3 The distribution of canine *L. infantum* infection in Europe.

Solano-Gallego et al. Parasites & Vectors 2011

hotspot; 2.5 milion dogs + ca. 900 human cases

Leishmaniosi: segni clinici

234 casi *unibo*

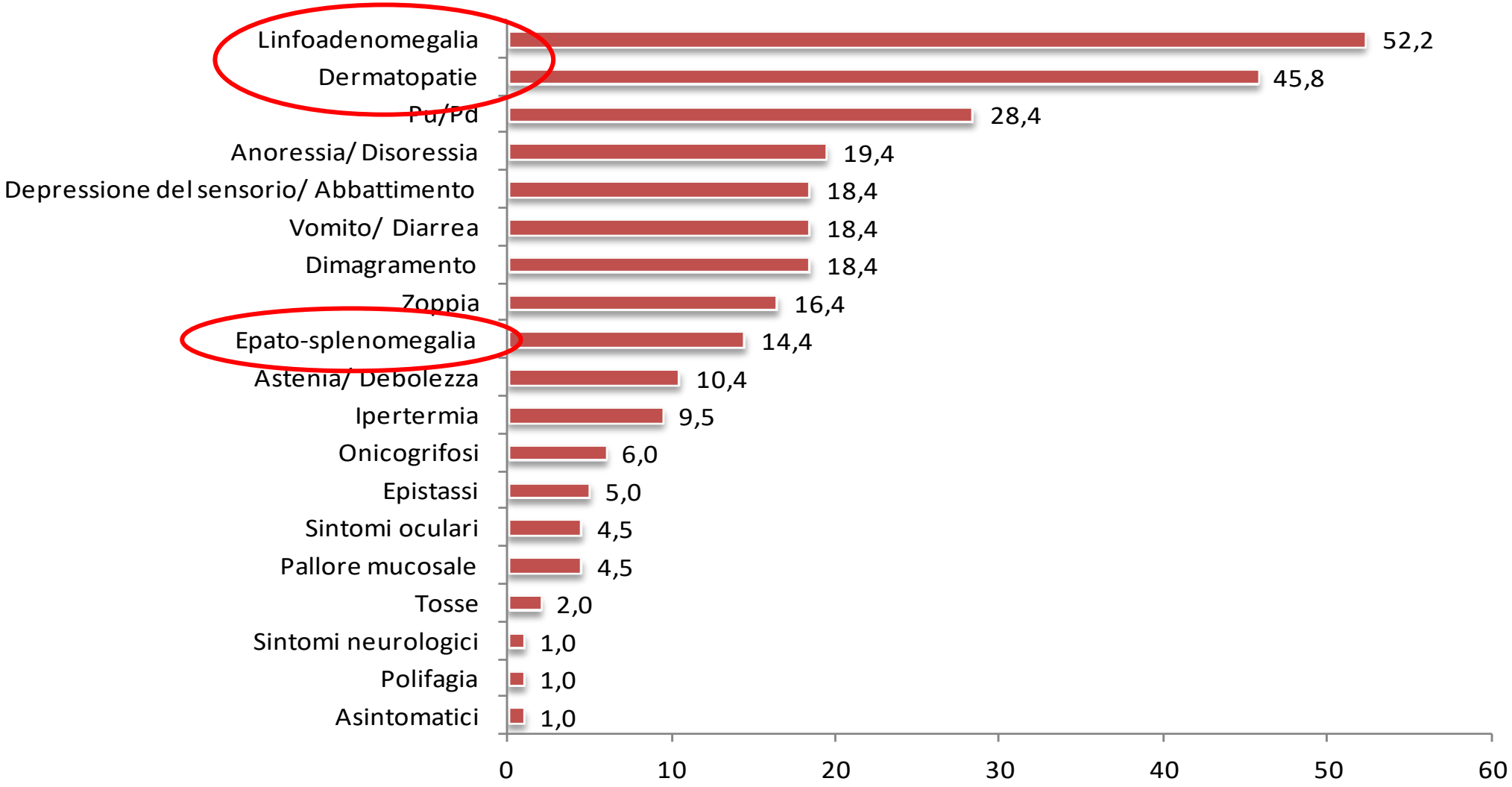

Linfoadenonegalia generalizzata – diagnosi differenziali

- malattie infettive/infezioni disseminate

  Virus/funghi/parassiti, malattie granulomatose

  Ehrlichiosi, ***Leishmaniosi***, Borreliosi …

  Dermatopatie diffuse

- malattie immunomediate/autoimmuni

  Lupus eritematoso sistemico, poliartriti, cellulite giovanile

  Reazione a farmaci (es.:ciclosporina)

- neoplasie "emopoietiche"

  linfoma, neoplasie istiocitarie (sarcoma istiocitario), leucemie …

- metastasi ai linfonodi

Splenomegalia – diagnosi differenziali

Congestione

Infarto splenico

Iperplasia

Emopoiesi extramidollare

Ematoma

Infiammazione/infezione →

- **Virali**
  - Epatite infettiva (adenovirus)
- **Rickettsial and Mycoplasmal**
  - Ehrlichiosi and anaplasmosi
  - Rickettsiosi ?
- **Batteriche**
  - Batteriemia
  - Bartonellosi
  - Brucellosi
  - Endotossemia
  - Borreliosi (Lyme)
  - Salmonellosi
- Tularemia
- **Micobatteri**
- **Micosi**
- **Protozoi**
  - Babesiosi
  - Hepatozoonosi
  - ***Leishmaniosi***
  - Toxoplasmosi

Masse spleniche (neoplastiche e non neoplastiche)

Neoplasie

S.J.Ettinger, E.C.Feldman, E.Cote; Textbook of veterinary internal medicine: diseases of the dog and the cat. 8th edition. Elsevier, [2017]

Hindawi Publishing Corporation
Veterinary Medicine International
Volume 2014, Article ID 374613, 5 pages
http://dx.doi.org/10.1155/2014/374613

Research Article

Prevalence of Dermatological Presentations of Canine Leishmaniasis in a Nonendemic Area: A Retrospective Study of 100 Dogs

Roberta Perego, Daniela Proverbio, Giada Bagnagatti De Giorgi, and Eva Spada

Dipartimento di Scienze Animali Per la Salute, la Produzione Animale e la Sicurezza Alimentare, University of Milan, Via Celoria 10, 20133 Milan, Italy

Table 1: Distribution of dermatological manifestation of CanL in all 100 dogs and in 21 dogs in the group with only dermatological manifestations of CanL and no identifiable systemic signs.

	Number of subjects	Prevalence
Dermatological form or manifestation in 100 dogs		
Exfoliative dermatitis with or without alopecia	74	74%
Ulcerative dermatitis	18	18%
Nodular form	11	11%
Onychogryphosis	10	10%
Nasal and digital hyperkeratosis	9	9%
Nasal depigmentation	1	1%
Sterile pustular dermatitis	1	1%

Dobermann
Femmina
3 anni

Setter inglese
Femmina
8 anni

Meticcio
Maschio
4 anni

Meticcio
Maschio
10 Anni

Sospetta
neoplasia

Meticcio
Maschio
5 anni

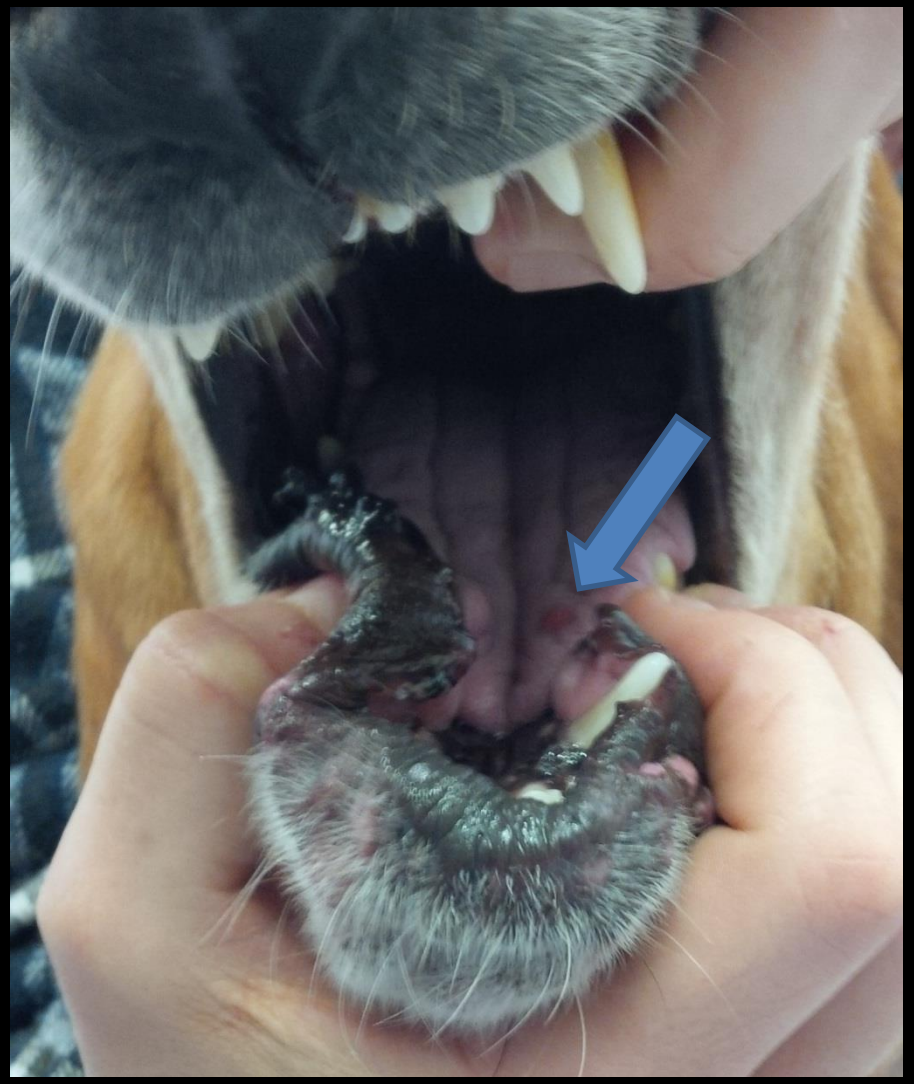

«Fred»
Basset Hound
Maschio
7 anni

IFI 1:80
Istologia e PCR positiva
sulle lesioni linguali

Cortesia Prof. Gaetano Oliva

«Fred»
Basset Hound
Maschio
7 anni

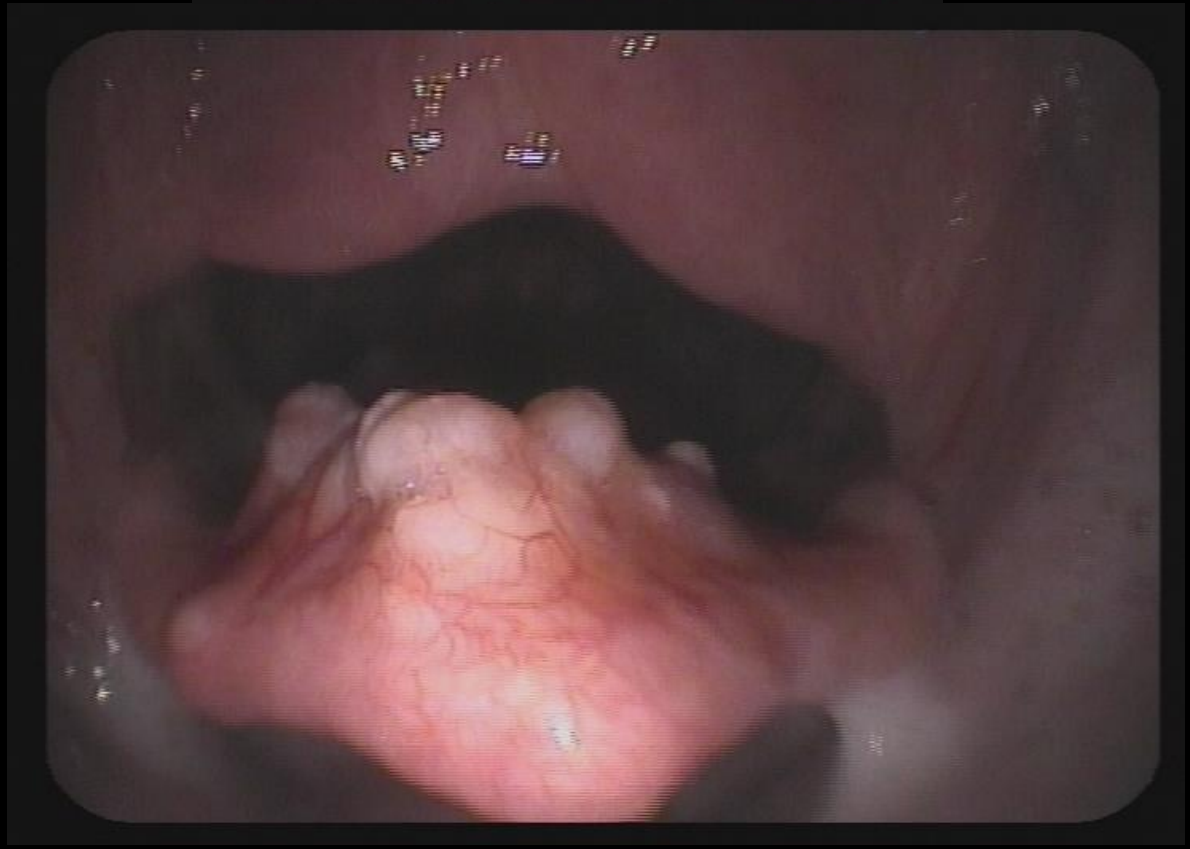

«Fred»
Basset Hound
Maschio
7 anni

Flogosi cronica + PCR positiva
sulle lesioni laringee

J. Comp. Path. 2018, Vol. 158, 6–11

Available online at www.sciencedirect.com

ScienceDirect

ELSEVIER

www.elsevier.com/locate/jcpa

INFECTIOUS DISEASE

Laryngeal Granuloma due to *Leishmania* spp. Infection in a Dog

E. Torrent[*,†], J. Pastor[†], L. Fresno[*,†], I. Vigueras[*,†], M. I. Casanova[‡], A. Ramis[‡] and L. Solano-Gallego[†]

[*] *Fundació Hospital Clínic Veterinari,* [†] *Departament de Medicina i Cirurgia Animals, Facultat de Veterinària and* [‡] *Departament de Sanitat i Anatomia Animals, Servei de Diagnòstic de Patologia Veterinària, Universitat Autònoma de Barcelona, Edifici V, Campus UAB, Bellaterra, Spain*

Summary

A French bulldog with a previous history of leishmaniosis was presented due to respiratory distress associated with a laryngeal mass. The mass was excised and cytological and histopathological examination revealed pyogranulomatous inflammation with *Leishmania* spp. amastigotes. After surgery, the respiratory condition resolved; however, 3 months later the dog developed clinicopathological signs of leishmaniosis, which improved with systemic treatment. This case shows an atypical presentation of leishmaniosis with a focal tumour-like mass in the vocal folds as the only clinical sign.

© 2017 Elsevier Ltd. All rights reserved.

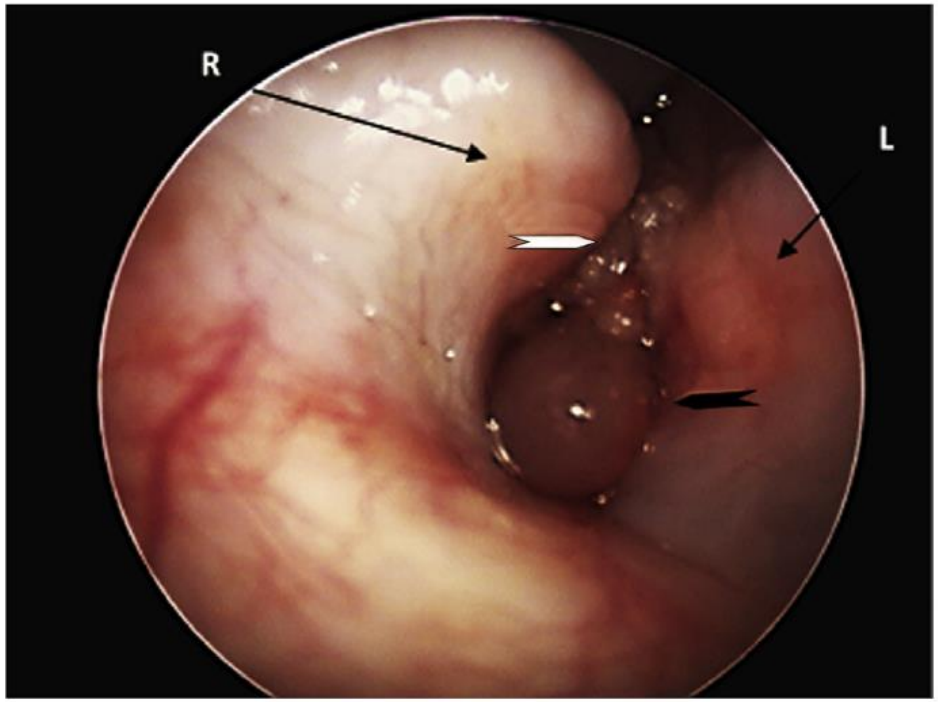

Fig. 1. Laryngoscopical examination showing an exophytic mass (▷) dorsal to the everted left laryngeal saccule (➡). R, right arytenoid cartilage; L, left arytenoid cartilage.

Veterinary Ophthalmology (2000) **3**, 35–41

Ocular and periocular manifest
cases (1993–1998)

M. T. Peña,* X. Roura* and M. G. Davidson†

*College of Veterinary Medicine, Autonomous University of Barcelona, B
State University, Raleigh, NC 27606, USA

Table 1 Distribution of ocular lesions in 105 dogs (210 eyes) with leishmaniasis

Ocular sign	Affected eyes (%)	Prevalence
Anterior uveitis	90	42.8%
Periocular alopecia	56	26.7%
Diffuse blepharitis	54	25.7%
Ulcerative blepharitis	8	3.8%
Solitary eyelid nodule	2	0.09%
vitis	66	31.4%
junctivitis	66	31.4%
junctivitis sicca	6	2.8%
uveitis	8	3.8%
lulitis	4	1.9%

38 M. T. PEÑA *ET AL.*

Figure 1.

s with ocular lesions had improvement in
cal anti-inflammatory therapy, although
term topical therapy. Response of ocular
esponse to therapy. Ophthalmic
mon in the dog, and this disease should be
adnexal and anterior segment ocular

e, keratoconjunctivitis, leishmaniasis

Leishmaniosi: segni clinici

234 casi *unibo*

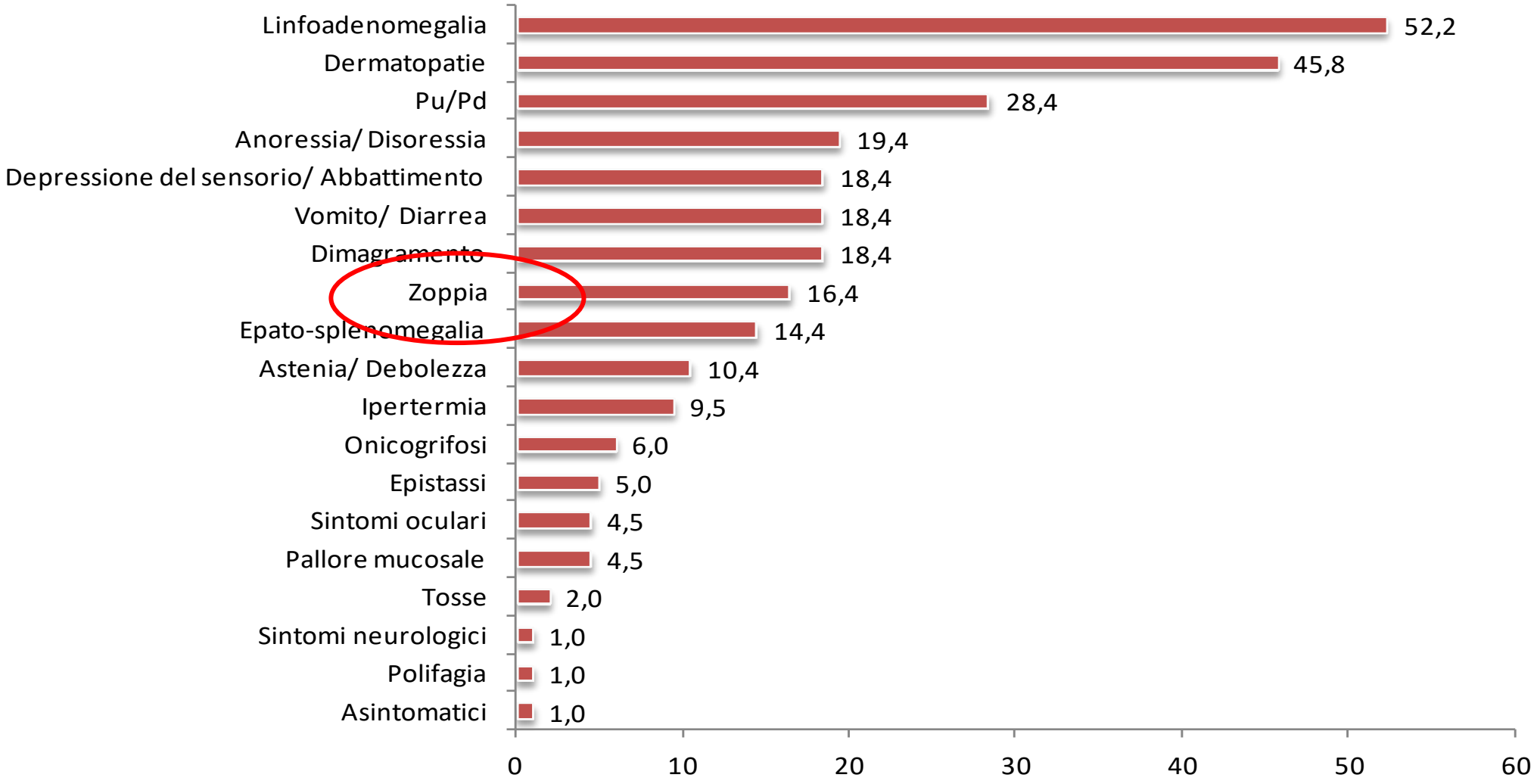

Zoppia e Leishmaniosi – diagnosi differenziale

Poliartrite immunoediata

Coinvolgimento osseo

Miosite

S.J.Ettinger, E.C.Feldman, E.Cote; Textbook of veterinary internal medicine: diseases of the dog and the cat. 8th edition. Elsevier, [2017]

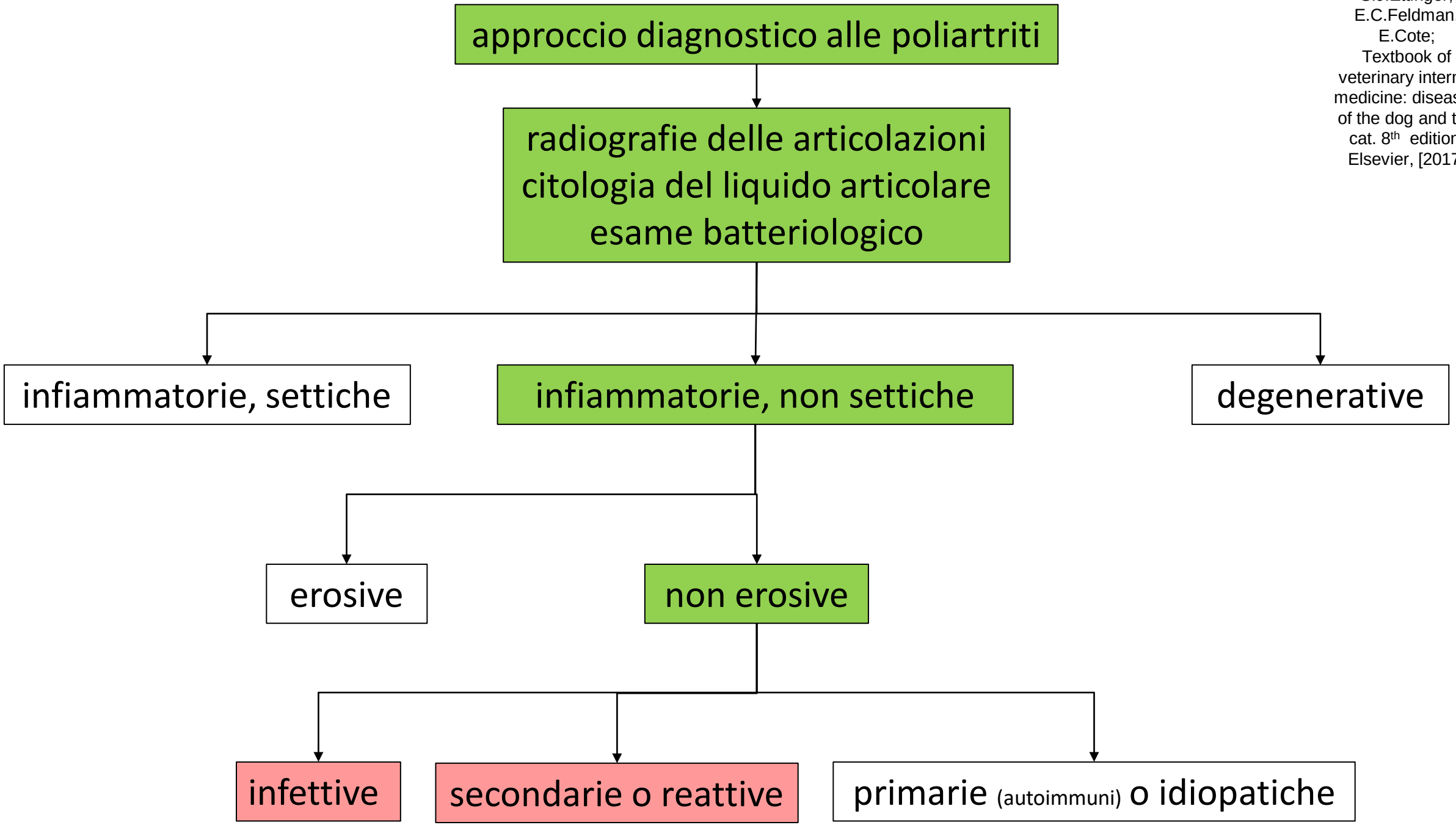

Poliartriti immunomediate - infettive

Lo stimolo immunogeno è nell'articolazione !!

- Batteri (Gram positivi, raramente +articolazioni)
- Rickettsie
- *Anaplasma/Ehrlichia spp.*
- *Borrelia burgdorferi*
- Micoplasmi
- ***Leishmania spp.***
- Funghi
- Virus

Retrospective study of 14 cases of canine arthritis secondary to *Leishmania* infection

Journal of Small Animal Practice (2014) **55**, 309–313
DOI: 10.1111/jsap.12204

Accepted: 30 January 2014; Published online: 3 April 2014

S. Sbrana*, V. Marchetti*, F. Manciantí†, G. Guidi* and D. Bennett‡

Table 2. Breed, age, sex, weight, general clinical signs and orthopaedic findings in the dogs in the study

Case	Breed	Age (months)	Sex	Weight (kg)	General clinical signs	Orthopaedic complain	Lameness score
1	Schnauzer	84	F	33	Lymphadenomegaly, Splenomegaly	Generalised stiffness and pain	1
2	Epagneul Breton	74	M	13	None	Generalised stiffness and pain	1
3	Crossbreed	48	F	21	Weakness, Lymphadenomegaly, Dermatitis	Generalised stiffness and pain	1
4	Crossbreed	60	F	38	Lymphadenomegaly, Splenomegaly, Dermatitis, Weakness	Generalised stiffness and pain	1
5	Crossbreed	32	M	34	Hyperthermia, Lymphadenomegaly	Generalised stiffness and pain	1
6	Crossbreed	72	M	7	Alopecia, Severe diffuse pain, Weakness	Generalised stiffness and pain	1
7	Crossbreed	62	F	10	None	Generalised stiffness and pain	1
8	Labrador retriever	120	M	38	None	Bilateral hindlimb lameness	2
9	Crossbreed	65	M	46	None	R hindlimb lameness	2
10	Crossbreed	15	F	21	Lymphadenomegaly, Splenomegaly, Dermatitis	Bilateral fore limb lameness	3
11	Rottweiler	60	M	45	Lymphadenomegaly	Bilateral hindlimb lameness	3
12	Crossbreed	72	M	42	None	Bilateral hindlimb lameness	3
13	Crossbreed	60	F	25	Lymphadenomegaly, Dermatitis	L fore limb lameness	4
14	Crossbreed	72	M	45	None	R fore limb lameness	4

M Male, F Female, L Left, R Right

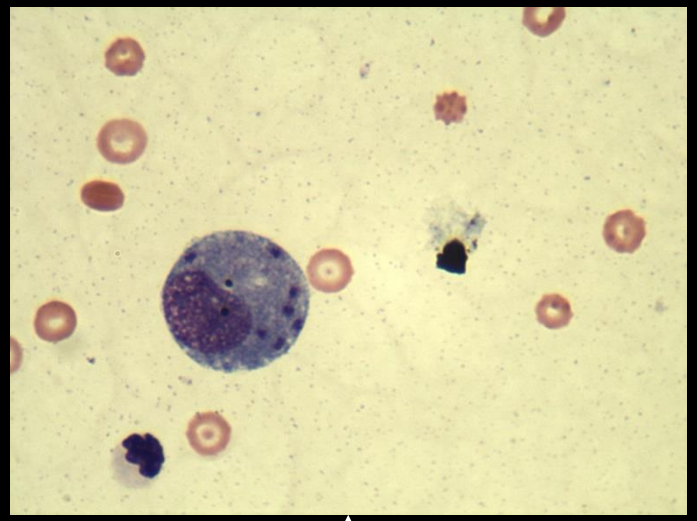

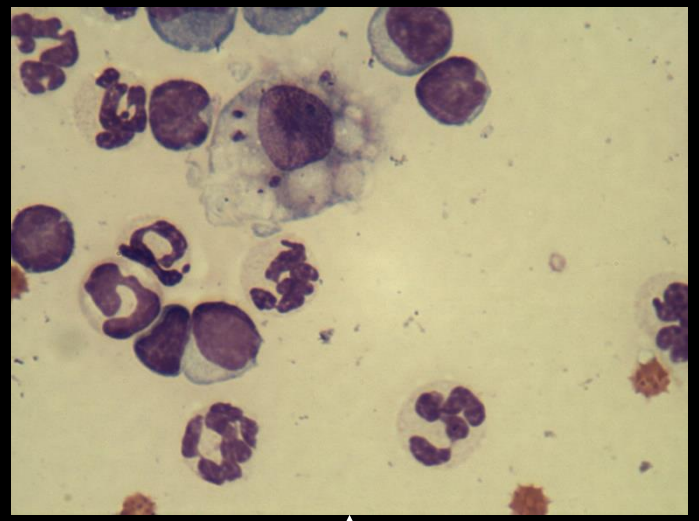

Liquido sinoviale

Linfonodi

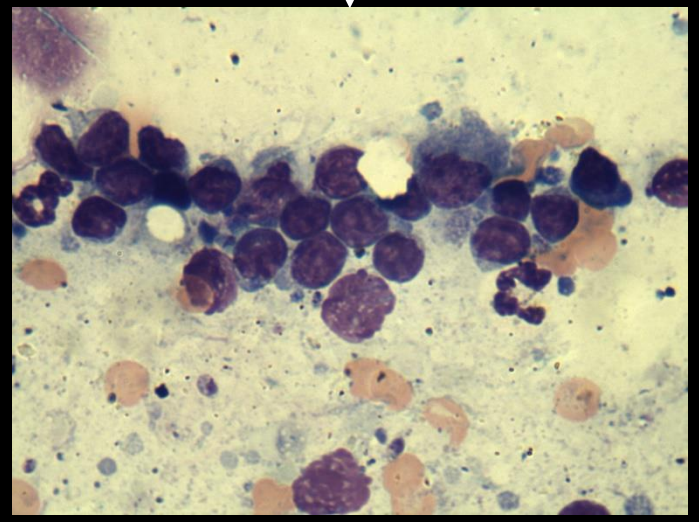

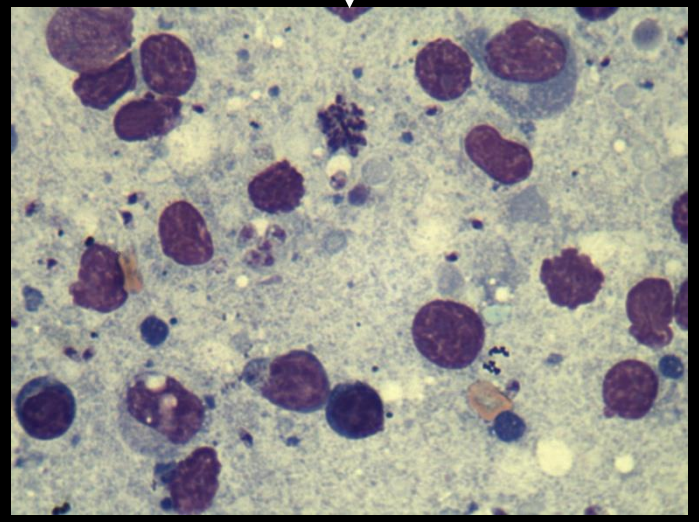

Liz
Beauceron
FS
Anni 4

Zoppia
Febbre
Iperproteinemia

Provenienza: Ravenna

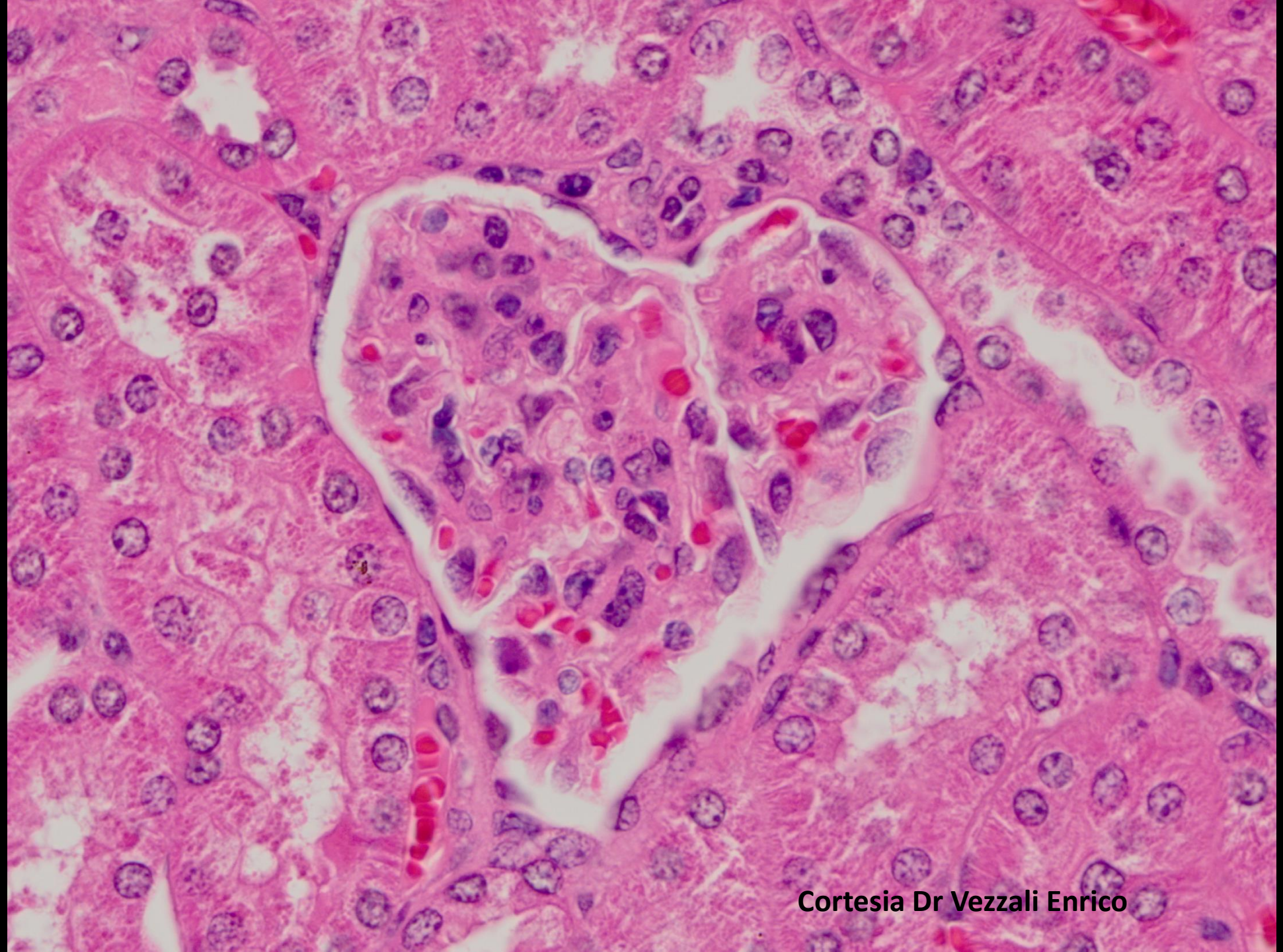
Cortesia Dr Vezzali Enrico

Principali cause di glomerulopatia/glomerulonefrite nel cane

Neoplastiche
- Leucemie
- Linfoma
- Mastocitoma
- Eritrocitosi primaria (policitemia)
- Istiocitosi sistemica/sarcoma istiocitario
- Altre neoplasie

Infettive/infiammatorie
- Borreliosi (malattia di Lyme)
- Bartonellosi
- Brucellosi
- Endocarditi
- Piometra
- Prostatite/ascesso prostatico
- Pielonefrite
- Piodermiti
- Infezioni batteriche croniche

- Babesiosi
- Leishmaniosi
- Filariosi

- Ehrlichiosi/Anaplasmosi

- Adenovirus canino tipo 1 (epatite di Rubarth)

- Micosi sistemiche



Infiammatorie non-infettive
- Dermatopatie croniche
- IBD
- Pancreatite
- Poliartriti immunomediate
- Lupus eritematoso sistemico
- Patologie immunomediate/autoimmuni in generale
  - anemia emolitica trombocitopenia (IMHA, IMT)

Altro
- Sindrome di Cushing/somministrazione di steroidi
- Idiopatico

Leishmaniosi e Glomerulopatie

Proteinuria come unico reperto clinicopatologico in molti pazienti !

Quadri clinici legati a:

- glomerulonefrite e **proteinuria**
- CKD
- sindrome nefrosica (proteinuria+edemi)

Prognosi peggiore e ***sopravvivenza minore***

Leishmaniosi: alterazioni clinicopatologiche

	Tipiche	Frequenti	Occasionali
CBC - Leucociti		neutrofilia	linfopenia Linfocitosi, eosinofilia
CBC - Eritrociti	anemia normocitica-normocromica non rigenerativa		test di Coombs +
CBC - Piastrine			trombocitopenia → co-infezioni
Emostasi		↓antitrombina	↑ PT e aPTT ipercoagulabilità (TEG)
Chimica clinica	iperazotemia ↑PT, ↓ albumine,↓ A/G		danno altri tessuti ?
Elettroforesi	gammopatia policlonale	gammopatia oligoclonale	gammopatia mono- o biclonale
Proteine di fase acuta	↑ CRP e APPs ↓ TIBC		
Analisi urinaria	Proteinuria allo stick, ***↑ PU/CU***, ↓ USG		

Paltrinieri et al. VCP 2016

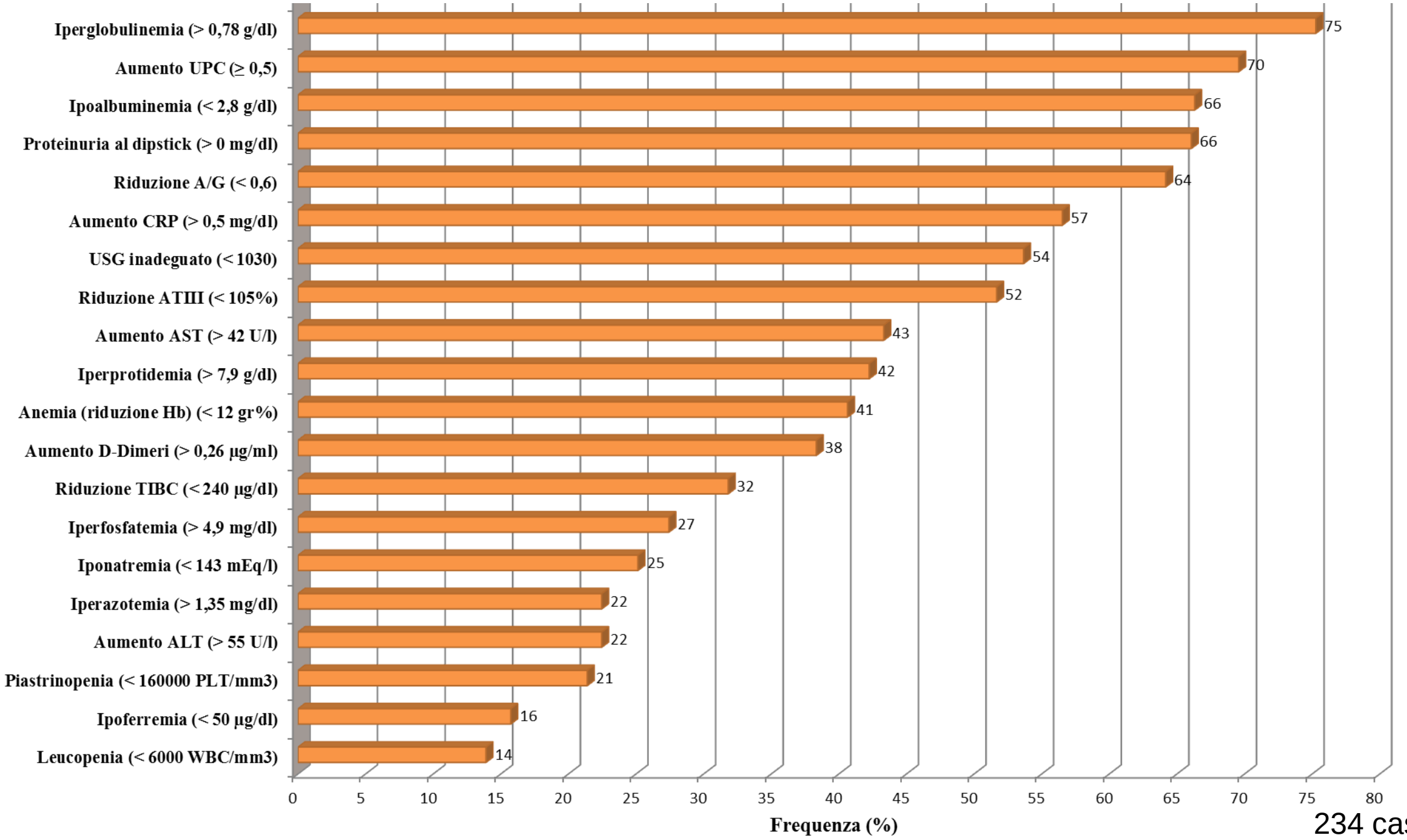

234 casi *unibo*

Terapia leishmaniosi

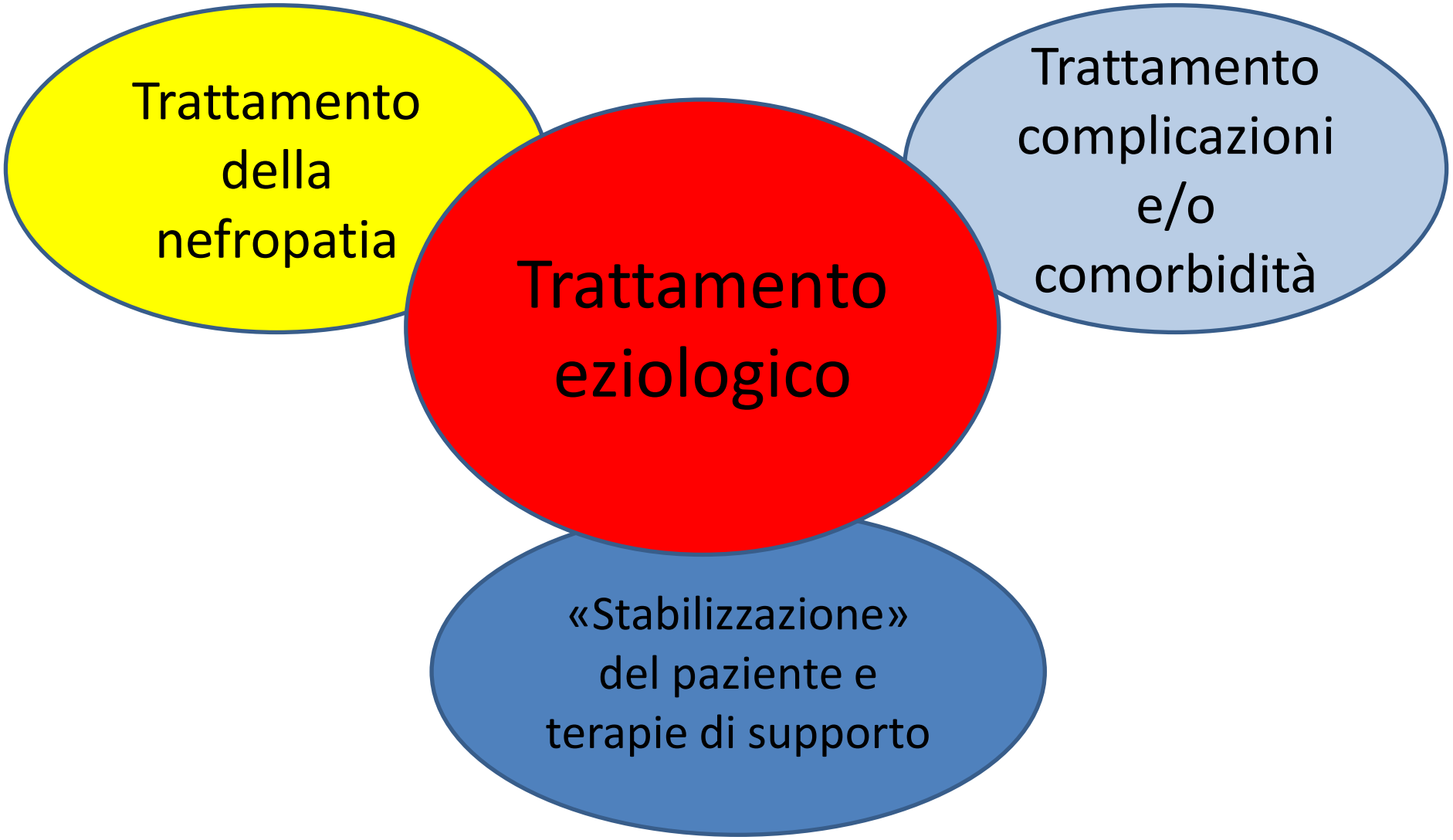

Terapia - scopi

Cura *clinica* o cura *parassitologica*?



- miglioramento clinico e clinicopatologico
- ↓ titolo Ab
- *shift* risposta umorale → cellulo-mediata
- riduzione immunocomplessi

Terapia - stadiazione

STADI CLINICI	SIEROLOGIA*	SEGNI CLINICI	DATI DI LABORATORIO	TERAPIA	PROGNOSI
STADIO I Malattia lieve	Sieronegativo o titolo anticorpale basso	Cani con segni clinici lievi come aumento di volume di un singolo linfonodo o dermatite papulosa	Generalmente non si osservano alterazioni clinico-patologiche. Profilo renale normale: creatinina < 1.4 mg/dl; non proteinurico: UPC < 0.2	Scientificamente negletto **/ Monitoraggio della progressione della malattia (vedi tabella 3)	Buona
STADIO II Malattia moderata	Titolo anticorpale da basso a elevato	Cani che, oltre ai segni clinici elencati per lo Stadio I, possono presentare altri segni clinici quali: lesioni cutanee simmetriche o diffuse come dermatite esfoliativa/onicogrifosi, ulcere (tartufo, cuscinetti plantari, prominenze ossee, giunzioni muco-cutenee), linfoadeno-megalia generalizzata, perdita di appetito, perdita di peso	Alterazioni clinico-patologiche come lieve anemia non rigenerativa, iper-gammaglobulinemia, ipoalbuminemia, sindrome da iperviscosità sierica. **Sottostadio** a) profilo renale normale: creatinina < 1.4 mg/dl; non proteinurico: UPC < 0.5 b) creatinina <1.4 mg/dl; UPC= 0.5-1	Allopurinolo + antimoniato di meglumina o miltefosina	Da buona a riservata
STADIO III Malattia grave	Titoli anticorpali da medi a elevati	Cani che, oltre ai segni clinici elencati negli Stadi I e II, possono presentare segni causati da lesioni da immuno-compessi (e.g. uveite e glomerulonefrite)	Alterazioni clinico-patologiche elencate nello Stadio II Insufficienza renale cronica (IRC) in stadio IRIS I con UPC= 1-5 o stadio II (creatinina 1.4-2 mg/dl)***	Allopurinolo + antimoniato di meglumina o miltefosina Secondo le linee guida IRIS per IRC***	Da riservata a infausta
STADIO IV Malattia molto grave	Titoli anticorpali da medi a elevati	Cani con segni clinici elencati nello Stadio III. Tromboembolismo polmonare o sindrome nefrosica e malattia renale allo stadio finale	Alterazioni clinico-patologiche elencate nello Stadio II, stadio IRIS III (creatinina 2.1-5 mg/dl) e stadio IV (creatinina>5 mg/dl) *** o sindrome nefrosica: marcata proteinuria UPC>5	Deve essere instaurato un trattamento specifico in maniera individualizzata Secondo le linee guida IRIS per IRC***	Infausta

*Cani sieronegativi o con titolo anticorpale da basso a medio dovrebbero ricevere una conferma dell'infezione attraverso l'impiego di altre tecniche diagnostiche quali citologia, istologia/immunoistochimica e PCR. Alti titoli anticorpali sono sufficienti per una diagnosi di CanL quando superano di 3-4 volte il cut-off di riferimento validato del laboratorio.

**Cani nello Stadio I (malattia lieve) probabilmente richiedono trattamenti meno prolungati con uno o due farmaci associati (allopurinolo, domperidone, antimoniato di meglumina o miltefosina) o in alterativa solo il monitoraggio senza terapia. Le informazioni sui cani in questo stadio sono limitate e, inoltre, le possibili opzioni terapeutiche devono ancora essere definite.

***http://iris-kidney.com/guidelines/staging.html

****http://iris-kidney.com/guidelines/recommendations.html

Terapia - stadiazione

STADI CLINICI	SIEROLOGIA*	SEGNI CLINICI	DATI DI LABORATORIO	TERAPIA	PROGNOSI
STADIO I Malattia lieve	Sieronegativo o titolo anticorpale basso	Cani con segni clinici lievi come aumento di volume di un singolo linfonodo o dermatite papulosa	Generalmente non si osservano alterazioni clinico-patologiche. Profilo renale normale: creatinina < 1.4 mg/dl; non proteinurico: UPC < 0.2	Scientificamente negletto **/ Monitoraggio della progressione della malattia (vedi tabella 3)	Buona
STADIO II Malattia moderata	Titolo anticorpale da basso a elevato	Cani che, oltre ai segni clinici elencati per lo Stadio I, possono presentare altri segni clinici quali: lesioni cutanee simmetriche o diffuse come dermatite esfoliativa/onicogrifosi, ulcere (tartufo, cuscinetti plantari, prominenze ossee, giunzioni muco-cutenee), linfoadeno-megalia generalizzata, perdita di appetito, perdita di peso	Alterazioni clinico-patologiche come lieve anemia non rigenerativa, iper-gammaglobulinemia, ipoalbuminemia, sindrome da iperviscosità sierica. **Sottostadio** a) profilo renale normale: creatinina < 1.4 mg/dl; non proteinurico: UPC < 0.5 b) creatinina <1.4 mg/dl; UPC= 0.5-1	Allopurinolo + antimoniato di meglumina o miltefosina	Da buona a riservata
STADIO III Malattia grave	Titoli anticorpali da medi a elevati	Cani che, oltre ai segni clinici elencati negli Stadi I e II, possono presentare segni causati da lesioni da immuno-compessi (e.g. uveite e glomerulonefrite)	Alterazioni clinico-patologiche elencate nello Stadio II Insufficienza renale cronica (IRC) in stadio IRIS I con UPC= 1-5 o stadio II (creatinina 1.4-2 mg/dl)***	Allopurinolo + antimoniato di meglumina o miltefosina Secondo le linee guida IRIS per IRC***	Da riservata a infausta
STADIO IV Malattia molto grave	Titoli anticorpali da medi a elevati	Cani con segni clinici elencati nello Stadio III. Tromboembolismo polmonare o sindrome nefrosica e malattia renale allo stadio finale	Alterazioni clinico-patologiche elencate nello Stadio II, stadio IRIS III (creatinina 2.1-5 mg/dl) e stadio IV (creatinina>5 mg/dl) *** o sindrome nefrosica: marcata proteinuria UPC>5	Deve essere instaurato un trattamento specifico in maniera individualizzata Secondo le linee guida IRIS per IRC***	Infausta

*Cani sieronegativi o con titolo anticorpale da basso a medio dovrebbero ricevere una conferma dell'infezione attraverso l'impiego di altre tecniche diagnostiche quali citologia, istologia/immunoistochimica e PCR. Alti titoli anticorpali sono sufficienti per una diagnosi di CanL quando superano di 3-4 volte il cut-off di riferimento validato del laboratorio.

**Cani nello Stadio I (malattia lieve) probabilmente richiedono trattamenti meno prolungati con uno o due farmaci associati (allopurinolo, domperidone, antimoniato di meglumina o miltefosina) o in alterativa solo il monitoraggio senza terapia. Le informazioni sui cani in questo stadio sono limitate e, inoltre, le possibili opzioni terapeutiche devono ancora essere definite.

***http://iris-kidney.com/guidelines/staging.html

****http://iris-kidney.com/guidelines/recommendations.html

TERAPIA

Tabella 3. Protocolli terapeutici attuali per CanL.

Farmaci	Dosaggio	Principali effetti collaterali
Antimoniato di meglumina [a]	100 mg/kg SC, SID o suddivisi in due dosi, per 4-6 setimane (una riduzione del dosaggio per i primi 2-3 giorni può essere utile per valutare eventuali effetti collaterali) [b]	→ Potenziale nefrotossicità → Dolore e infiammazione nel sito di inoculo
Miltefosina [a]	2mg/kg PO, una volta al giorno per 28 giorni	→ Vomito → Diarrea
Alopurinolo	10 mg/kg PO, due volte al giorno per almeno 6-12 mesi	→ Urolitiasi da xantina

Domanda

Per monitorare un cane dopo il trattamento, cosa faresti?

1. PCR quantitativa
2. Sierologia
3. Proteine di fase acuta
4. Valutazione clinica e gli esami di base

Recommended monitoring during and after treatment of CanL

PARAMETERS	FREQUENCY	
	Sick treated dogs	**Clinically healthy infected dogs**
➔ Clinical history and physical examination ➔ CBC, biochemical profile ± serum electrophoresis ➔ Complete urinalysis ±UPC	After the first month of treatment and then every 3-4 months during the first year. Later on, every 6-12 months in dogs fully recovered clinically with treatment.	Every 3-6 months
➔ Quantitative serology*	Not before 6 months after initial treatment and every 6-12 months.	Every 3-6 months
➔ Real-time PCR (optional)	At the same time as serology.	Every 3-6 months

Ringraziamenti:

Sofia Segatore
Roberta Troìa
Chiara Grisetti
Erika Monari
Kateryna Vasylyeva
Silvia Zamagni
Alessandro Tirolo
Linda Perissinotto
Lorenza Urbani

Tutti i colleghi della UO di Nefrologia e Urologia
Dell'Ospedale veterinario universitario

f.dondi@unibo.it

Leishmaniosi: cosa utilizzo per una diagnosi definitiva?

- Sierologia:
  - Rapida o quantitativa?
- Citologia:
  - Quale substrato?
- Biologia molecolare:
  - Quale substrato?
  - Che tipo ?

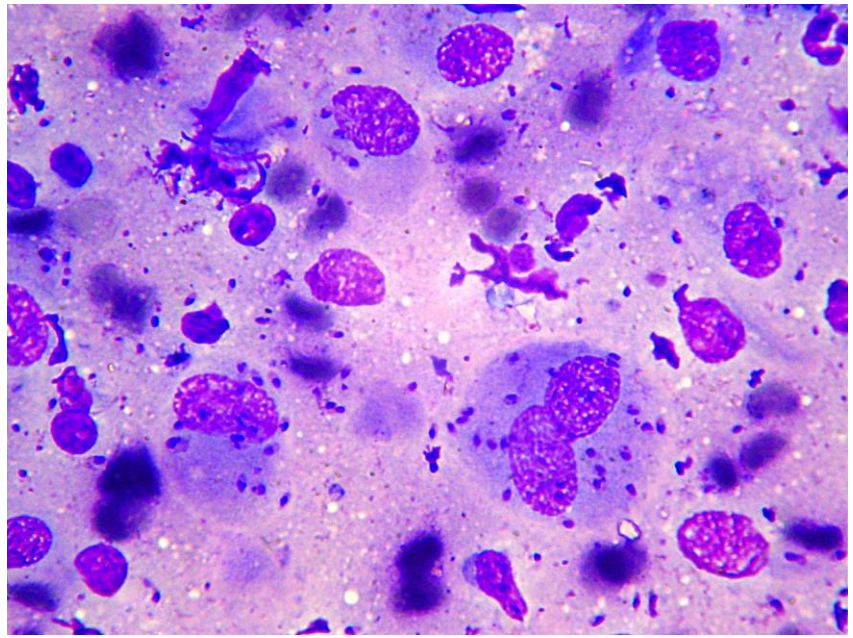

Diagnosi di Leishmaniosi → Sierologia

Test disponibili:	**Pro**	**Contro**
Rapidi qualitativi	Semplici e rapidi Elevata specificità	Poco sensibili Non quantitativi
IFI	Sensibile Specifico a titoli alti	Time-consuming Operatore-dipendente Poco ripetibile
ELISA quantitativa	Sensibile Specifica a titoli elevati Oggettivabile	Strumentazione

Leishmaniosi: cosa utilizzo per una diagnosi definitiva?

- Sierologia:
  - Rapida o quantitativa?

- Citologia:
  - Quale substrato?

- Biologia molecolare:
  - Quale substrato?
  - Che tipo ?

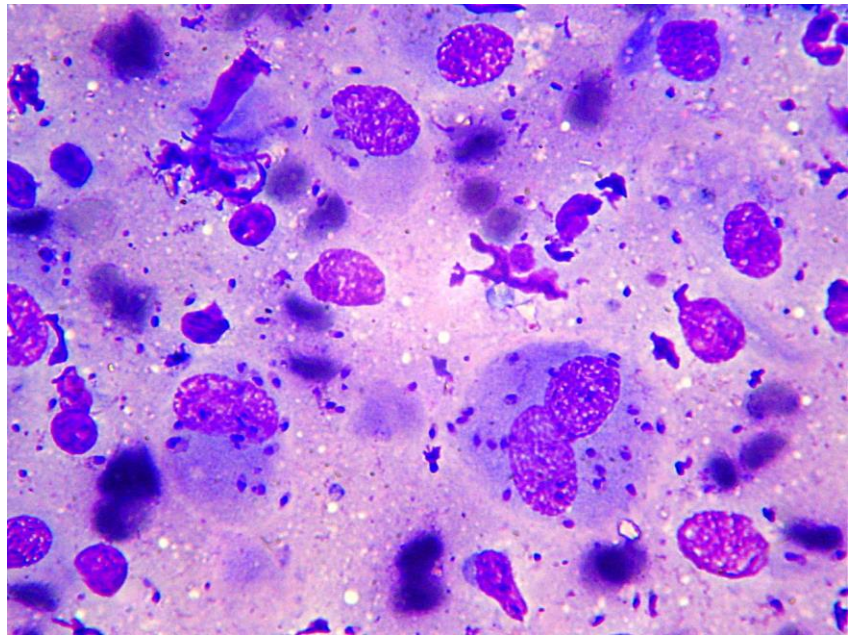

Dog with clinical signs and/or clinicopathological abnormalities consistent with CanL (in non-vaccinated)

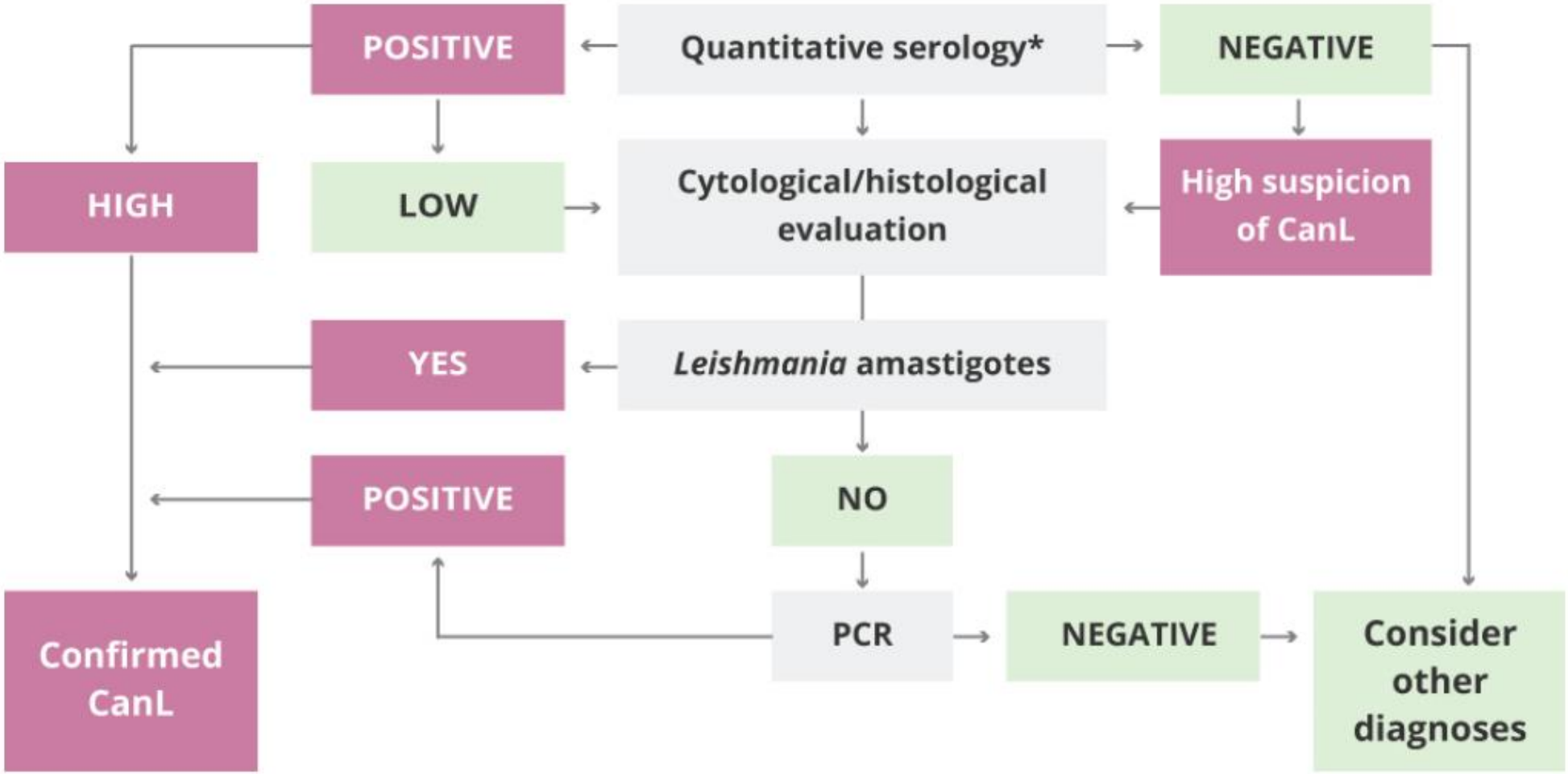

Leishmaniosi - Esami a confronto

- <u>Per lo screening iniziale</u>:
  - Sierologia e dati di base

- <u>Per la diagnosi definitiva</u>:
  - Citologia
  - PCR
  - (Sierologia alto titolo)

- Per il monitoraggio ???

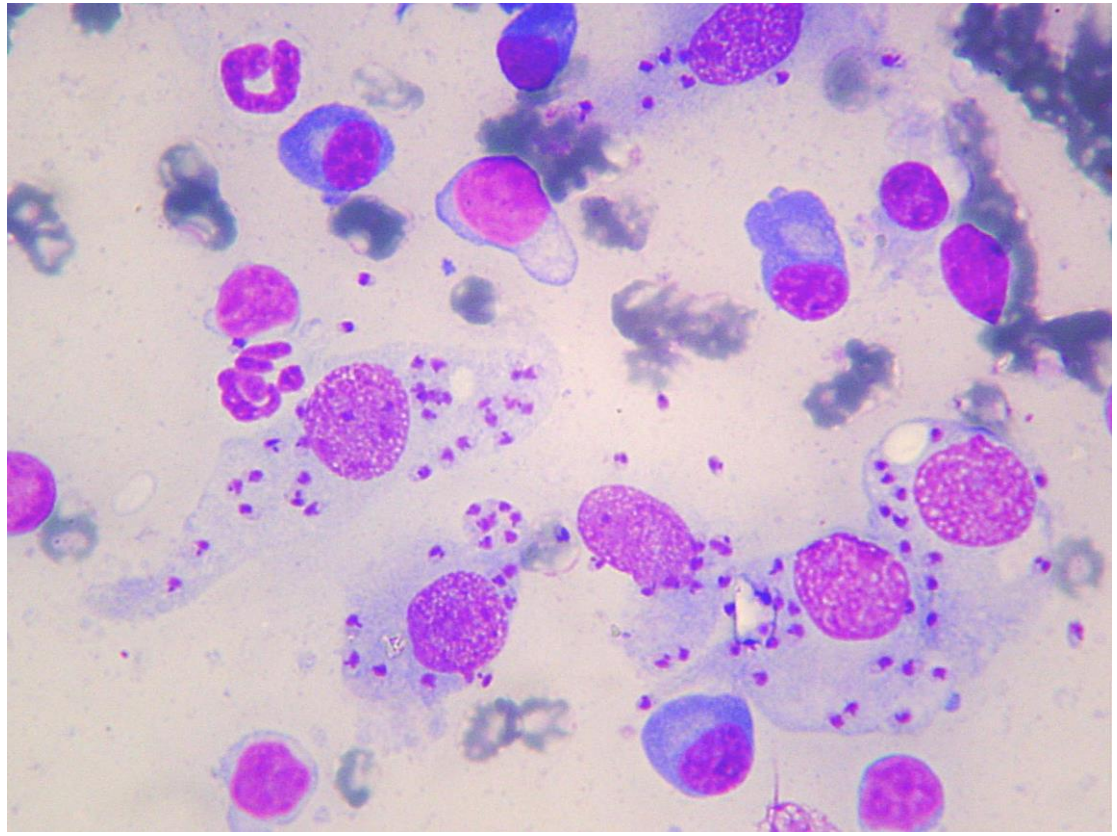

Poliartriti - Protocollo diagnostico

- Esame emocromocitometrico
- Profilo chimico + CRP
- Analisi urinaria
- Artrocentesi + citologia del liquido sinoviale (+ batteriologico)

  → almeno 4 articolazioni a prescindere dai segni clinici
- Radiografie arti
- Rx torace e ecografia addominale
- Test eziologici …

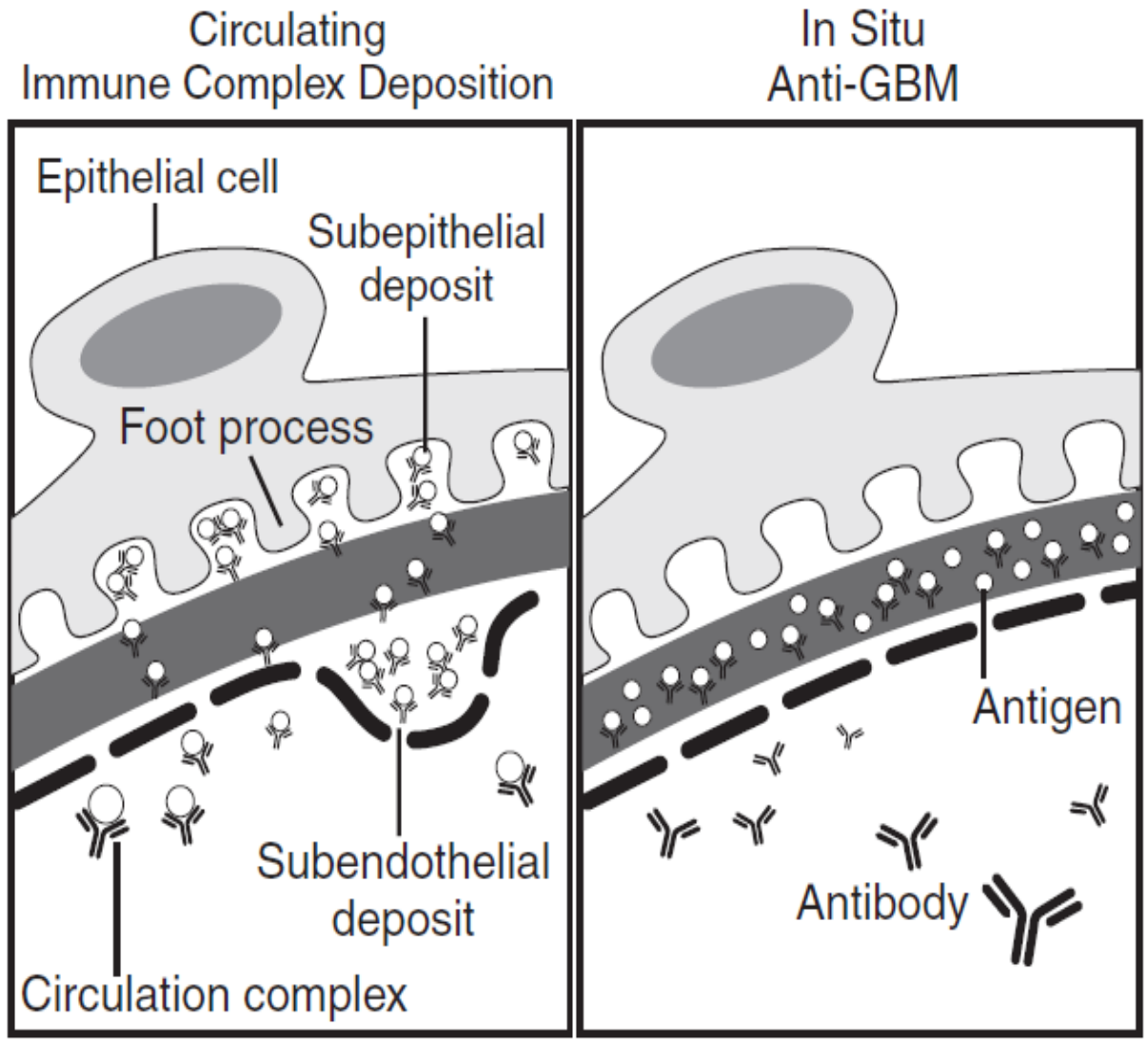

ELSEVIER

Available online at www.sciencedirect.com
ScienceDirect
Research in Veterinary Science 85 (2008) 510–514

RVS
www.elsevier.com/locate/rvsc

Anti-histone antibodies in dogs with leishmaniasis and glomerulonephritis

Pedro J. Ginel *, Soledad Camacho, Rosario Lucena

Department of Animal Medicine and Surgery, Faculty of Veterinary Medicine of Córdoba, University of Córdoba, Campus de Rabanales, 14014 Córdoba, Spain

Accepted 23 January 2008

Leishmaniosi e Miopatie

Danno diretto → presenza di amastigoti

Deposizione di immuno-complessi
correlato a vasculiti e anticorpi anti-miofibrociti

Istologia:
infiammazione linfoplasmocellulare e/o granulomatosa → fibrosi

Review

Pathologic Mechanisms Underlying the Clinical Findings in Canine Leishmaniosis due to *Leishmania infantum/chagasi*

Veterinary Pathology
2014, Vol. 51(2) 527-538
© The Author(s) 2014
Reprints and permission:
sagepub.com/journalsPermissions.nav
DOI: 10.1177/0300985814521248
vet.sagepub.com

A. F. Koutinas[1] and C. K. Koutinas[2]

Clinical and radiographic study of bone and joint lesions in 26 dogs with leishmaniasis

A. Agut, N. Corzo, J. Murciano, F. G. Laredo, M. Soler

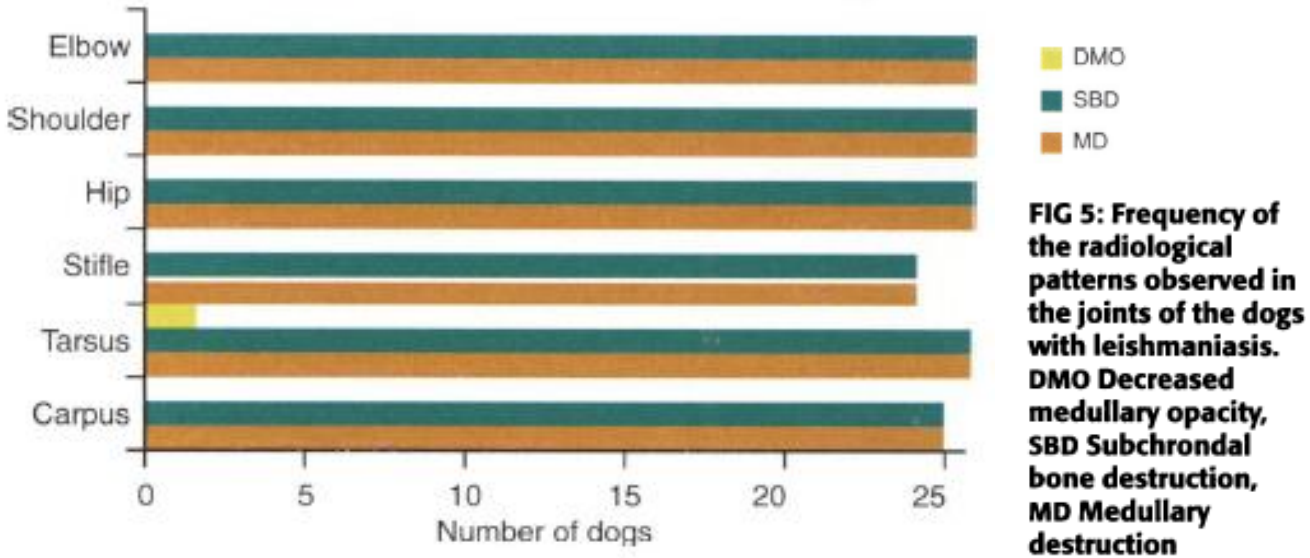

FIG 5: Frequency of the radiological patterns observed in the joints of the dogs with leishmaniasis. DMO Decreased medullary opacity, SBD Subchrondal bone destruction, MD Medullary destruction

1. Reazione granulomatosa legata alla presenza del parassita → ossa lunghe

2. Deposito di immuno-complessi a livello sinoviale & reazione di ipersensibilità di III tipo → neutrofili
   Alterazione articolazioni
   Vasculiti
   Aumento della permeabilità vascolare

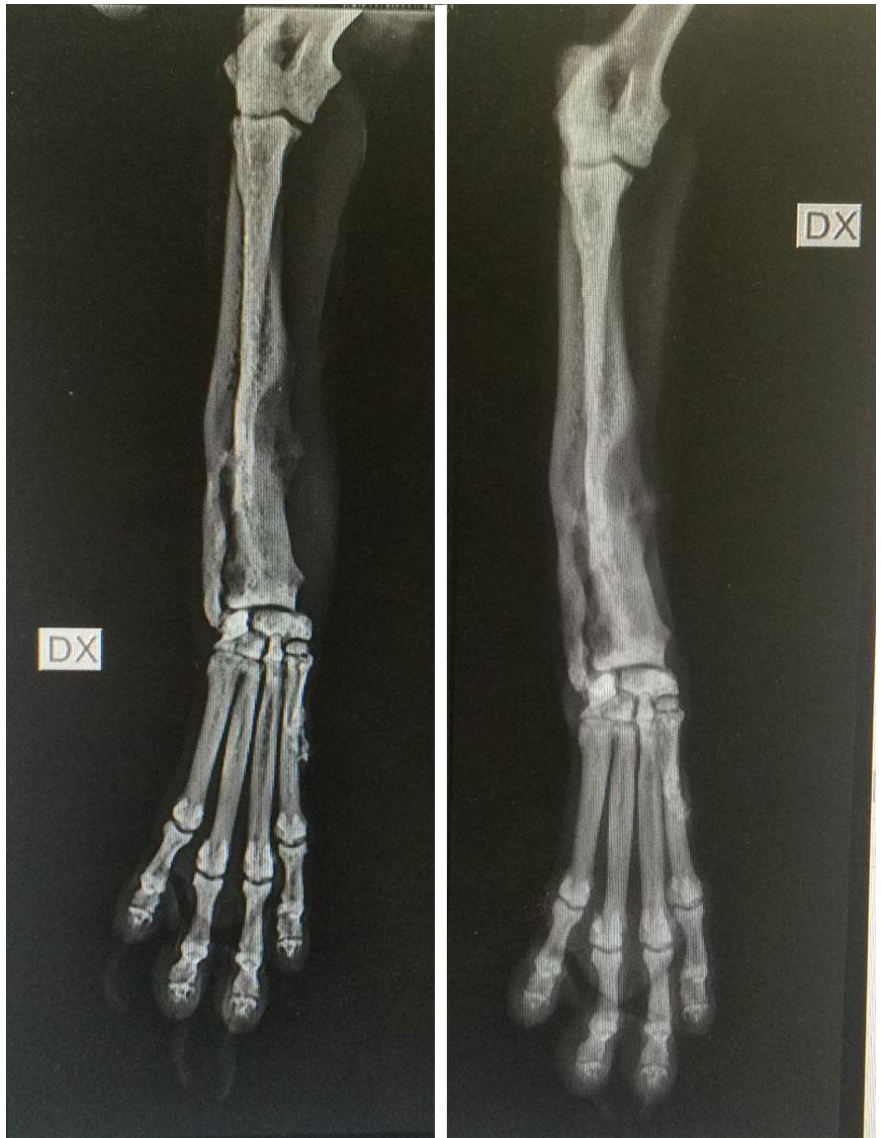
DX
DX

PAPER

A retrospective study of 61 cases of spontaneous canine epistaxis (1998 to 2001)

M. E. Mylonakis, M. N. Saridomichelakis*, V. Lazaridis, L. S. Leontides†, P. Kostoulas† and A. F. Koutinas

Companion Animal Clinic, Faculty of Veterinary Medicine, Aristotle University of Thessaloniki, 11 Stavrou Voutyra Str., 54627 Thessaloniki, Greece

*Clinic of Animal Medicine †Laboratory of Epidemiology, Biostatistics and Economics of Animal Production, School of Veterinary Medicine, University of Thessaly, 224 Trikalom Str., 43100 Karditsa, Greece

Journal of Small Animal Practice (2008) **49**, 191–196
DOI: 10.1111/j.1748-5827.2007.00441.x

A retrospective study of 61 cases of spontaneous canine epistaxis (1998 to 2001)

Table 1. Diagnoses established in 61 canine patients with spontaneous epistaxis

Diagnosis	Number of cases (%)
Systemic diseases (n=56)	
Leishmaniasis (*Leishmania infantum*)*	29 (48)
Monocytic ehrlichiosis (*Ehrlichia canis*)*	28 (46)†
Rodenticide toxicity	2 (3)
Immune-mediated thrombocytopenia	1 (2)
Suspected oestrogen toxicity	1 (2)
Systemic arterial hypertension	1 (2)
Intranasal diseases (n=5)	
Transmissible venereal tumour	3 (5)
Nasal adenocarcinoma	1 (2)
Nasal aspergillosis	1 (2)

*Six dogs (11 per cent) had concurrent leishmaniasis and monocytic ehrlichiosis
†Thirteen of the 28 dogs (46 per cent) were German shepherd dogs

J Vet Intern Med 2008;22:866–872

Factors Associated with the Occurrence of Epistaxis in Natural Canine Leishmaniasis (*Leishmania infantum*)

T.A. Petanides, A.F. Koutinas, M.E. Mylonakis, M.J. Day, M.N. Saridomichelakis, L.S. Leontides, R. Mischke, P. Diniz, E.B. Breitschwerdt, M. Kritsepi, V.A. Garipidou, C.K. Koutinas, and S. Lekkas

Background: Canine leishmaniasis (CanL) is a common cause of epistaxis in dogs residing in endemic areas. The pathogenesis of CanL-associated epistaxis has not been fully explored because of the limited number of cases reported so far.

Hypothesis: Epistaxis in CanL could be attributed to more than 1 pathomechanism such as hemostatic dysfunction, biochemical

Anim

Meth (n = 27) of epistaxis 1 *Aspergillus* spp.), bi

Resul regation response t axis than in those wi = .029) and γ-globul h was lower (P = .01

Clini ctors such as thrombocytopathy, hyperglobulinemia-induced serum hyperviscosity, and nasal mucosa ulceration.

In conclusion, the results of this study indicate that a single pathogenetic mechanism cannot invariably be incriminated for epistaxis in natural CanL, but rather the interaction of various internal factors such as thrombocytopathy, hyperglobulinemia-induced serum hyperviscosity, and ulcerative or nonulcerative rhinitis most likely is responsible.

Key words: Dysproteinemia; Rhinitis; Thrombocytopathy.

Myocarditis and generalised vasculitis associated with leishmaniosis in a dog

A three-year-old, female bulldog was presented with bilateral uveitis, apathy, listlessness, generalised lymphadenopathy and perivulvar haematoma. The initial laboratory studies showed non-regenerative anaemia, polyclonal gammopathy and a high urine protein:creatinine ratio. Serology for leishmaniosis was positive and treatment with allopurinol and meglumine antimoniate was started. Despite treatment, the dog's clinical condition deteriorated. Signs included cutaneous ecchymosis, respiratory distress and finally cardiorespiratory arrest. Histopathological studies of postmortem tissue samples revealed a generalised vasculitis of several internal organs and severe myocarditis. *Leishmania* species organisms were identified in affected tissues using immunoperoxidase labelling and PCR techniques.

E. Torrent, M. Leiva, J. Segalés*, J. Franch, T. Peña, B. Cabrera* and J. Pastor

Journal of Small Animal Practice (2005) **46**, 549–552

INTRODUCTION

Canine leishmaniosis is an infectious disease, caused by a protozoon of the genus *Leishmania*, that affects people and wild and domestic animals (Slappendel and Ferrer 1998). The disease is endemic in

Clinical signs of leishmaniosis are caused by the parasite itself and by an exuberant B cell activity that generates large numbers of circulating immune complexes, the deposition of which may lead to polyarthritis, uveitis, glomerulonephritis and vasculitis (López and others 1996). In canine leishmaniosis, some common skin lesions are attributed to vasculitis (Affolter 1997). However, the presence of generalised internal vascular lesions has been less commonly recognised (Pumarola and others 1991). Leishmaniosis involving myocarditis has only rarely been reported (Büngener and Mehlitz 1977, Font and others 1993).

This case report describes an unusual presentation of leishmaniosis that included generalised vasculitis and myocarditis in a dog.

CASE HISTORY

A three-year-old, entire female bulldog with chronic keratoconjunctivitis sicca was treated surgically for entropion and dystrichiasis. After surgery and resolution of the keratitis, a bilateral panuveitis was

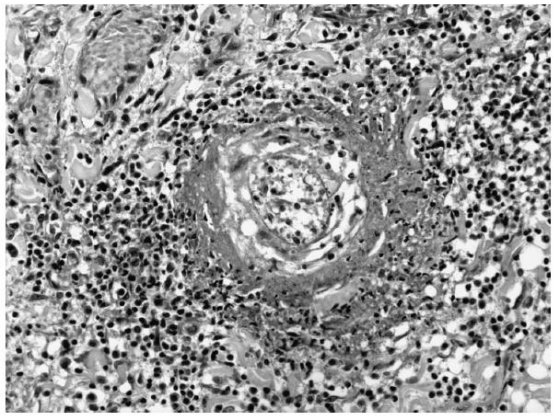

FIG 2. Myocardium from the dog. Necrotising vasculitis characterised by hyaline necrosis of the vascular wall, which is infiltrated by necrotic inflammatory cells and surrounded by mononuclear (lymphocytes, plasma cells and macrophages) infiltrates. Haematoxylin and eosin (H&E). x200

Rodi
Pastore tedesco
MC
10 anni

Pregressa positività a Leishmania IFI: 1:320
Trattato anni prima con :
antimoniali+allopurinolo

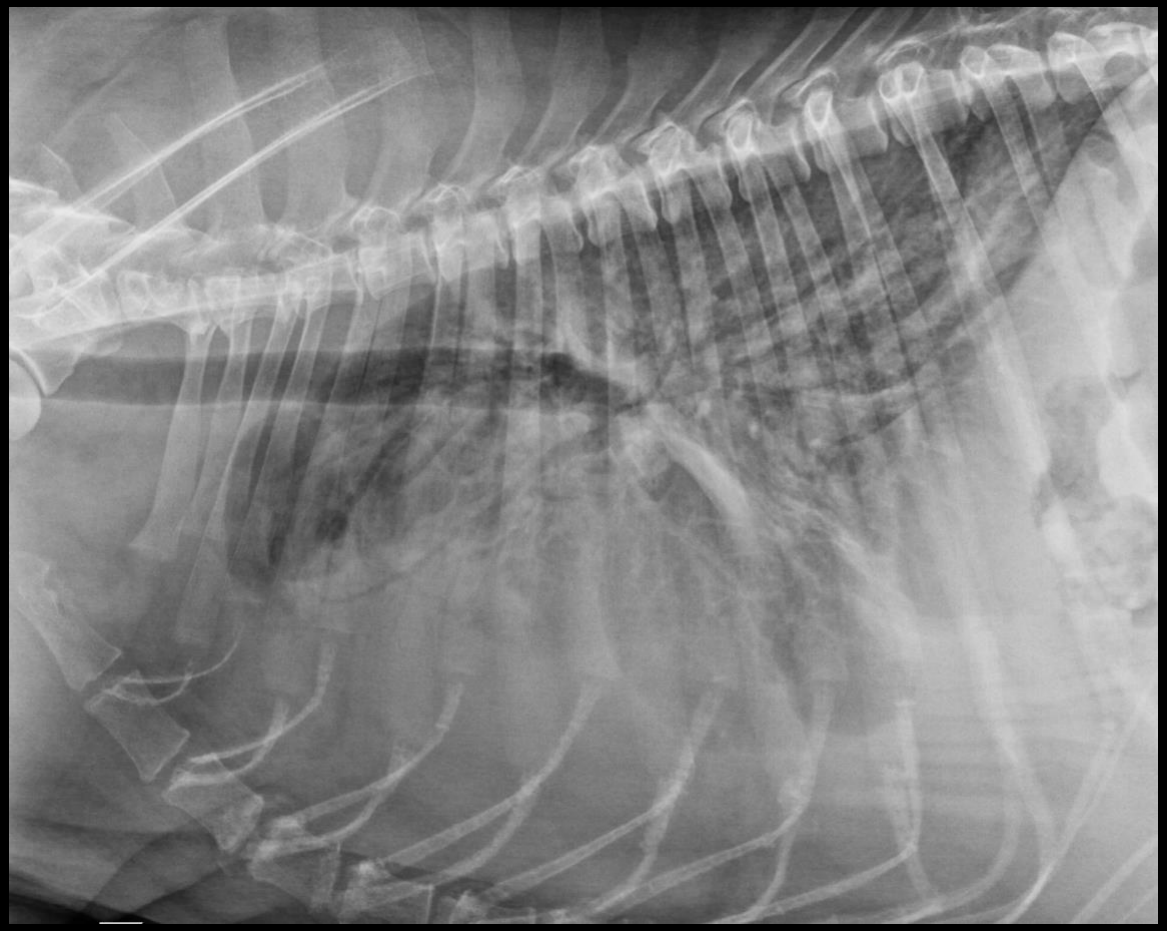

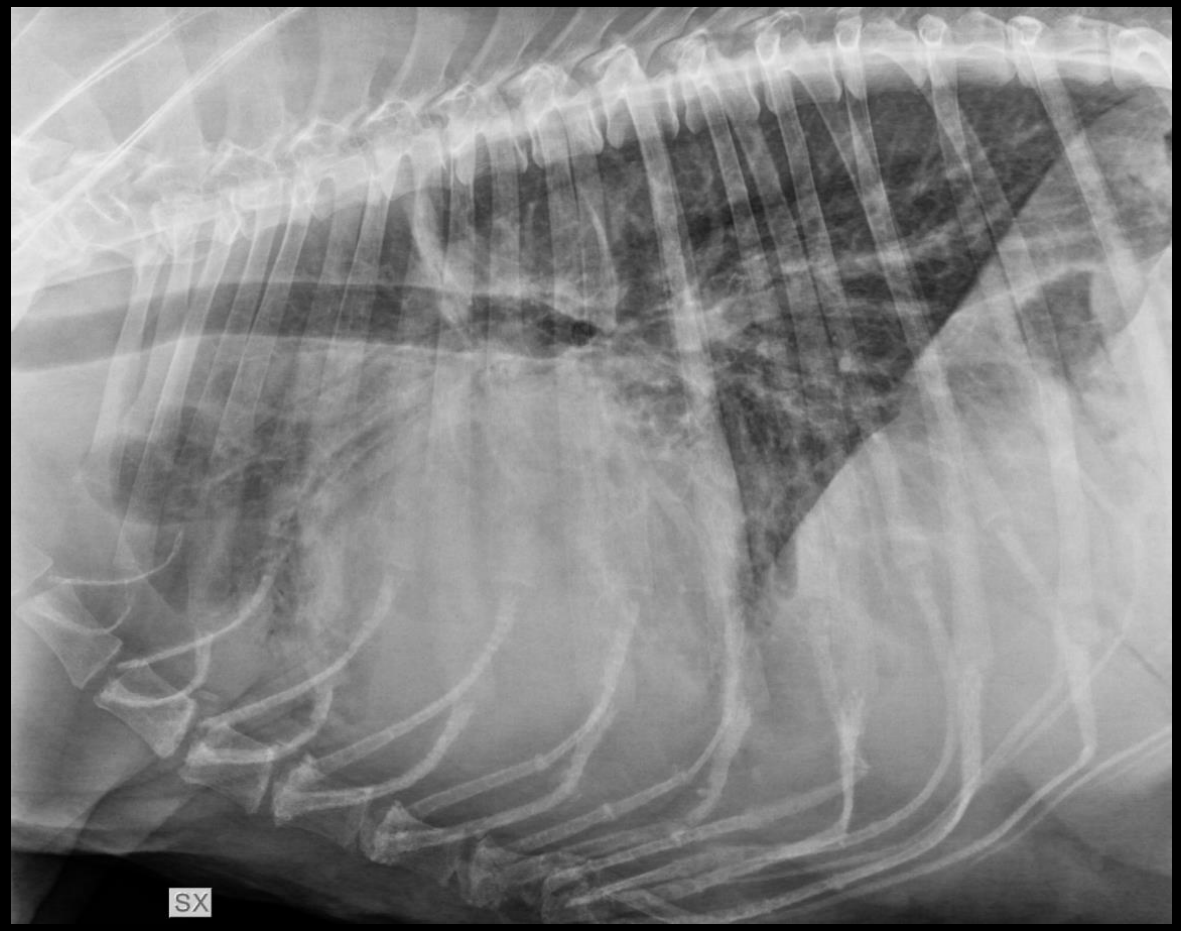

Journal of Veterinary Cardiology (2019) 23, 32—37

ELSEVIER

Journal of Veterinary Cardiology
ESVC

www.elsevier.com/locate/jvc

Case Report

Canine leish
pericardial

P. Sebastián-Mar
S. Gómez, DVM,
PhD[a,c]

[a] Division of Veterinary
Veterinary Faculty, Univ
[b] Department of Compar
University of Murcia, Co
[c] Department of Animal
Campus Espinardo, 301C

Received 4 February 2018;

Abstract A 4-year-old crossbreed dog presented with a two-day history of lethargy and abdominal effusion. Physical examination and echocardiography revealed pericardial effusion with cardiac tamponade. Pericardiocentesis was performed. Intracytoplasmic *Leishmania* amastigotes were found on cytological examination of the pericardial fluid. The animal was treated with N-methylglucamine antimoniate and allopurinol. After an initial favorable response, cardiac tamponade reoccurred one month later. The dog died during a pericardiectomy four months after the initial diagnosis. Histology confirmed the presence of chronic pericarditis. The presence of *Leishmania* amastigotes on cytological examination of pericardial effusion suggests a possible association between canine leishmaniasis and chronic pericarditis. This finding also supports the importance of cytological examination of pericardial fluid in areas endemic for canine leishmaniasis.
© 2019 Elsevier B.V. All rights reserved.

REVIEW

Neurological manifestations in dogs naturally infected by *Leishmania infantum*: descriptions of 10 cases and a review of the literature

A. P. Giannuzzi, M. Ricciardi, A. De Simone and F. Gernone[1]

Pingry Veterinary Hospital, Bari, 70126, Italy

[1]Corresponding author email: flogernone@gmail.com

In order to evaluate possible nervous system involvement in canine leishmaniasis, retrospective evaluation of all medical records of leishmaniotic dogs exhibiting neurological signs referred to our hospital over a 5-year period was performed. The records of 10 dogs were reviewed. Depending on the neuroanatomical localisation, the dogs underwent advanced diagnostic imaging, cerebrospinal fluid analysis, electrodiagnostic testing and histopathologic evaluations. The final neurological diagnosis was: meningoencephalitis (n=2), brain haemorrhagic stroke (n=1), haemorrhagic choroiditis (n=1), meningomyelitis (n=2), ischaemic myelopathy (n=1), polymyositis (n=2) and peripheral neuropathy (n=1). This study confirms that both central and peripheral nervous systems can be affected by leishmaniasis and provides an overview on the possible etiopathogenetic mechanisms. In addition, clinical and diagnostic findings, therapy and follow-up of affected dogs are described.

Journal of Small Animal Practice (2017) **58**, 125–138
DOI: 10.1111/jsap.12650

Accepted: 14 October 2016

Meccanismi patogenetici proposti:

1) effetto diretto del parassita

2) **lesioni immunomediate**

3) **vascultite** o altre lesioni vascolari

4) complicazioni legate a immunosoppressione

5) altre complicazioni

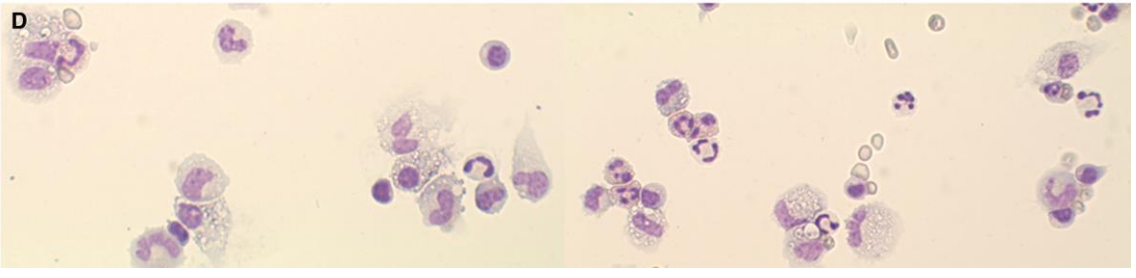

Immunopatologia e segni clinici – "casi atipici"

permanenza dell'antigene + «mimica molecolare» e liberazione antigeni criptici

produzione di autoanticorpi

anti-globuli rossi → IMHA

anti-piastrine → IMT

anti-granulociti → IMN ?

anti-nucleari → ANAtest+

anti-Ag cutanei → dermatopatie immunomediate ?

anti-istone → glomerulonefrite ?

} Reazioni di ipersensibilità di tipo II

Autoimmune manifestations in patients with visceral leishmaniasis

Journal of Microbiology, Immunology and Infection (2013) 46, 302–305

Evangelos Liberopoulos*, Anastazia Kei, Fotini Apostolou, Moses Elisaf

Table 2 Immune laboratory findings on admission[a]

Parameter (reference range)	
ANA (<1/160)	Elevated in 14 patients (88%): 1/480 (1/160–1/2560)
RF (<20 IU/mL)	Elevated in 10 patients (63%): 42.7 ± 35.9 IU/mL
C3 factor of complement (88–201 mg/dL)	Decreased in 2 patients (13%) 1st patient: 38 mg/dL 2nd patient: 44 mg/dL
C4 factor of complement (16–47 mg/dL)	Decreased in 8 patients (50%): 11.2 ± 4.5 mg/dL
Anti-cardiolipin antibodies (IgG)	Elevated in 2 patients (13%): 1st patient: 35 U/mL 2nd patient: 40 U/mL
Cryoglobulins	Detected in 8 patients (50%)
Coombs' test	• Direct: positive in 2 patients (13%) • Indirect: positive in 1 patient (6%)
β2-microglobulin (0–1900 μg/L)	Elevated in 4 patients (25%): 37,900 ± 23,800 μg/L
Hypergammaglobulinemia	• Polyclonal: 3 patients (19%) • Biclonal: 1 patient (6%) • Monoclonal: 6 patients (38%)
ASMA	Detected in 4 patients (25%) 1/160 (1/80–1/240)
p-ANCA	Detected in 4 patients (25%) 1/40 (1/20–1/80)
Anti-TPO/anti-TBG	Detected in 1 patient (6%)
Anti-ENA	Detected in 4 patients (25%)
Anti-MPO	Detected in 1 patient (6%)
Anti-Ro	Detected in 2 patients (13%)
Anti-Sm	Detected in 1 patient (6%)
Anti-ds-DNA	Not detected (0%)
Anti-PR3	Not detected (0%)

[a] Values are expressed as mean ± standard deviation, except for ANA, ASMA and p-ANCA, which are expressed as median (range). ANA = anti-nuclear antibody; anti-ds-DNA = anti-double-stranded-DNA antibody; anti-ENA = anti-extractable nuclear antigen antibody; anti-MPO = anti-myeloperoxidase antibody; anti-PR3 = anti-proteinase 3 antibody; anti-Sm = anti-Smith antibody; anti-TBG = anti-thyroxine binding globulin antibody; anti-TPO = anti-thyroid peroxidase antibody; ASMA = anti-smooth muscle cell antibody; p-ANCA = protoplasmic-staining anti-neutrophil cytoplasmic antibody; RF = rheumatoid factor.

AJVR, Vol 73, No. 9, September 2012

Perinuclear antineutrophil cytoplasmic autoantibodies in dogs infected with various vector-borne pathogens and in dogs with immune-mediated hemolytic anemia

Anna E. Karagianni, DVM, MRes; Laia Solano-Gallego, DVM, PhD; Edward B. Breitschwerdt, DVM; Frédéric P. Gaschen, Dr med vet, Dr habil; Michael J. Day, BVMS, PhD, DSc; Michele Trotta, DVM, PhD; Barbara Wieland, Dr med vet, PhD; Karin Allenspach, Dr med vet, PhD

Group	No. (%) of dogs with positive results for pANCA	95% CI
Dogs in which IMHA was diagnosed or suspected clinically (n = 55)		
IMHA diagnosed (n = 16)	11 (69)	46–92
IMHA suspected; positive result for Coombs' test (n = 19)	6 (32)	11–53
IMHA suspected; negative result for Coombs' test (n = 20)	9 (45)	23–67
Dogs confirmed or suspected of having vector-borne infections (n = 140)		
Clinically suspected and seroreactive for ≥ 1 tick-borne diseases including *Rickettsia rickettsii*, *Bartonella henselae*, *Bartonella vinsonii* subsp *berkhoffii*, *Ehrlichia canis*, and *Borrelia burgdorferi* infection (n = 97)	39 (40)	30–50
Clinically suspected and seroreactive for *Leishmania infantum* (n = 43)	28 (65)	51–79
Control dogs (n = 62)		
Dogs clinically suspected but seronegative for tick-borne pathogens (n = 20)	1 (5)	0–25
Dogs clinically suspected but seronegative for *L infantum* (n = 22)	8 (36)	20–57
Healthy dogs (n = 20)	1 (5)	0–25

Leishmaniosi e Citopenie immunomediate

Leishmaniosi e IMHA (anemia emolitica immunomediata)

Review Cellular Immunology 292 (2014) 9–13

Leishmaniasis and autoimmune diseases in pediatric age

M. Nozzi *, M. Del Torto, F. Chiarelli, L. Breda

Paediatric Rheumatology Unit, Department of Paediatrics, "G. d'Annunzio" University, Chieti, Italy

Numerosi case report in letteratura di bambini con IMHA secondaria a *L. infantum* *

Descritta anche sindrome di Evans *

* **Visceral leishmaniasis presented with Evans syndrome: a case report,** B. Alioglu, Z. Avci, E. Ozyurek, N. Ozbek, Am. J. Hematol. 82 (2007) 1030–1031.
* **Immune haemolytic anaemia due to visceral leishmaniasis in a young child**, M. Boel, Eur. J. Pediatr. 162 (2003) 444.
***Kala-azar associated with coombs-positive autoimmune hemolytic anemia in the patients coming from the endemic area of this disease and successful treatment of these patients with liposomal amphotericin B**, E. Erduran, A. Bahadir, Y. Gedik, Pediatr. Hematol. Oncol. 22 (2005) 349–355.
***Immune mediated hemolysis in visceral leishmaniasis,** V. Mahajan, R.K. Marwaha, J. Trop. Pediatr. 53 (2007) 284–286.

Leishmaniosi e Positività al test di Coombs → anemia emolitica immunomediata (IMHA) ?

Dati variabili in letteratura (21 - 84%*)

Mancanza di studi che correlino anemia & positività test di Coombs

→ Evidenza di IMHA ?

*__A retrospective clinical study of canine leishmaniasis in 150 dogs naturally infected by Leishmania infantum__, P. Ciaramella, G. Oliva, R. De Luna, L. Gradoni, R. Ambrosio, L. Cortese, A. Scalone, A. Persechino -Veterinary Record (1997) 141, 539-543

* **Canine Leishmaniasis, A review based on 95 cases in the Netherlands,** R. J. Slappendel - THE VETERINARY QUARTERLY, VOL. 10, No. 1, JANUARY 1988

Received: 13 December 2018 | Accepted: 18 January 2019

DOI: 10.1111/jvim.15441

CONSENSUS STATEMENT

Journal of Veterinary Internal Medicine Open Access

ACVIM American College of Veterinary Internal Medicine

Consensus Statements of the American College of Veterinary Internal Medicine (ACVIM) provide the veterinary community with up-to-date information on the pathophysiology, diagnosis, and treatment of clinically important animal diseases. The ACVIM Board of Regents oversees selection of relevant topics, identification of panel members with the expertise to draft the statements, and other aspects of assuring the integrity of the process. The statements are derived from evidence-based medicine whenever possible and the panel offers interpretive comments when such evidence is inadequate or contradictory. A draft is prepared by the panel, followed by solicitation of input by the ACVIM membership which may be incorporated into the statement. It is then submitted to the Journal of Veterinary Internal Medicine, where it is edited prior to publication. The authors are solely responsible for the content of the statements.

ACVIM consensus statement on the diagnosis of immune-mediated hemolytic anemia in dogs and cats

Oliver A. Garden[1] | Linda Kidd[2] | Angela M. Mexas[3] | Yu-Mei Chang[4] | Unity Jeffery[5] | Shauna L. Blois[6] | Jonathan E. Fogle[7] | Amy L. MacNeill[8] | George Lubas[9] | Adam Birkenheuer[7] | Simona Buoncompagni[10] | Julien R. S. Dandrieux[11] | Antonio Di Loria[12] | Claire L. Fellman[13] | Barbara Glanemann[4] | Robert Goggs[14] | Jennifer L. Granick[15] | Dana N. LeVine[16] | Claire R. Sharp[17] | Saralyn Smith-Carr[18] | James W. Swann[19] | Balazs Szladovits[4]

Diagnosi anemia emolitica immunomediata (IMHA) cane

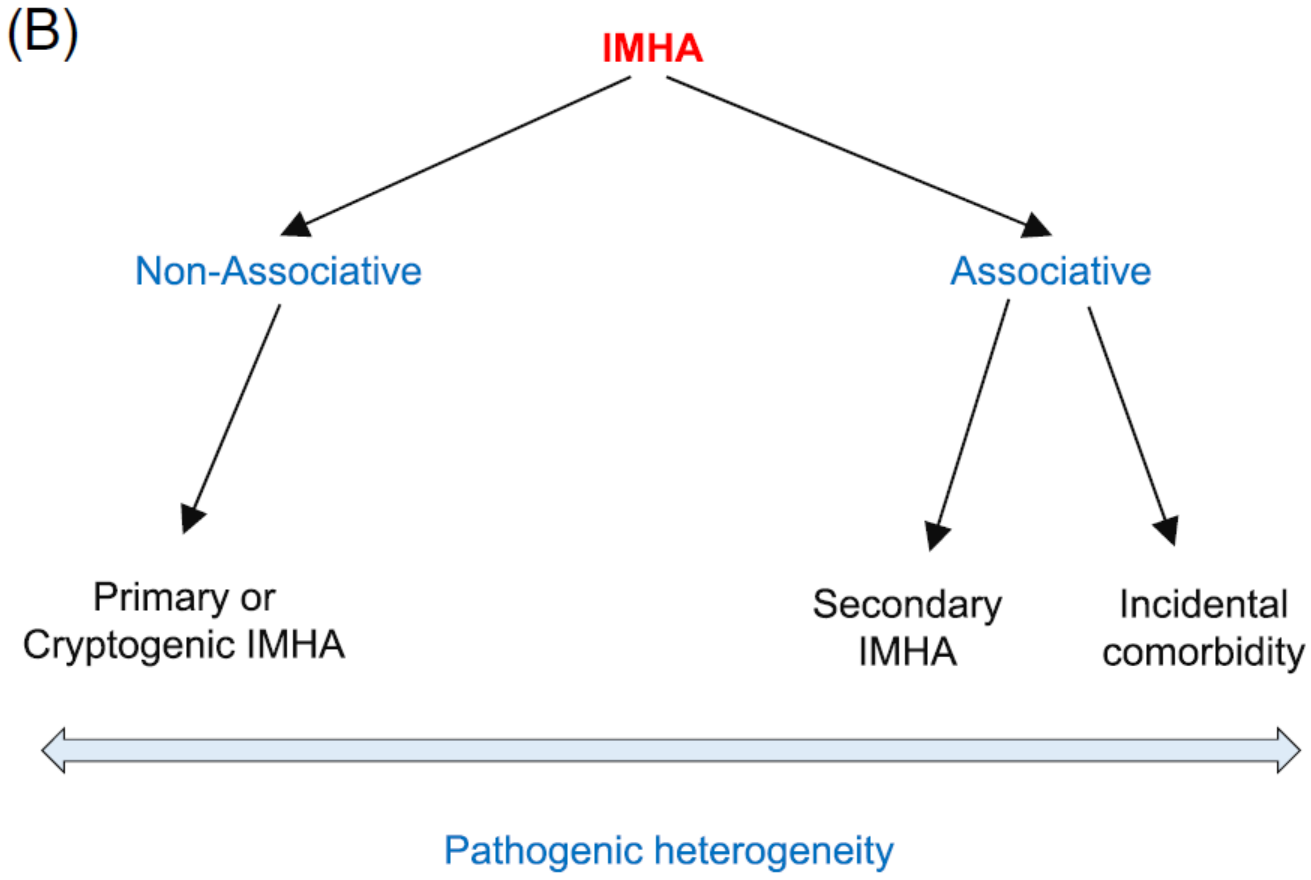

Nuova classificazione

Received: 13 December 2018 | Accepted: 18 January 2019
DOI: 10.1111/jvim.15441

CONSENSUS STATEMENT

Journal of Veterinary Internal Medicine Open Access ACVIM American College of Veterinary Internal Medicine

Consensus Statements of the American College of Veterinary Internal Medicine (ACVIM) provide the veterinary community with up-to-date information on the pathophysiology, diagnosis, and treatment of clinically important animal diseases. The ACVIM Board of Regents oversees selection of relevant topics, identification of panel members with the expertise to draft the statements, and other aspects of assuring the integrity of the process. The statements are derived from evidence-based medicine whenever possible and the panel offers interpretive comments when such evidence is inadequate or contradictory. A draft is prepared by the panel, followed by solicitation of input by the ACVIM membership which may be incorporated into the statement. It is then submitted to the Journal of Veterinary Internal Medicine, where it is edited prior to publication. The authors are solely responsible for the content of the statements.

ACVIM consensus statement on the diagnosis of immune-mediated hemolytic anemia in dogs and cats

Diagnosi anemia emolitica immunomediata (IMHA) cane

Anemia

Sferocitosi

Autoagglutinazione («saline agglutination test» positivo)

Anticorpi anti-RBCs ?

Iperbilirubunemia

Pigmenturia (emoglobinuria/bilirubinuria)

RBCs Ghosts (eritrociti fantasma)

+ identificazione di una potenziale causa

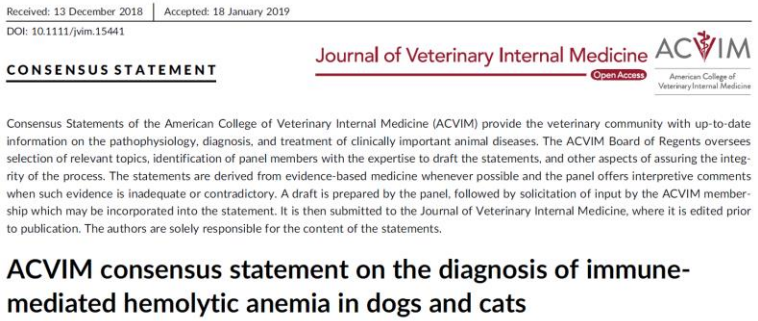

Received: 13 December 2018 | Accepted: 18 January 2019
DOI: 10.1111/jvim.15441

CONSENSUS STATEMENT

Journal of Veterinary Internal Medicine Open Access ACVIM American College of Veterinary Internal Medicine

Consensus Statements of the American College of Veterinary Internal Medicine (ACVIM) provide the veterinary community with up-to-date information on the pathophysiology, diagnosis, and treatment of clinically important animal diseases. The ACVIM Board of Regents oversees selection of relevant topics, identification of panel members with the expertise to draft the statements, and other aspects of assuring the integrity of the process. The statements are derived from evidence-based medicine whenever possible and the panel offers interpretive comments when such evidence is inadequate or contradictory. A draft is prepared by the panel, followed by solicitation of input by the ACVIM membership which may be incorporated into the statement. It is then submitted to the Journal of Veterinary Internal Medicine, where it is edited prior to publication. The authors are solely responsible for the content of the statements.

ACVIM consensus statement on the diagnosis of immune-mediated hemolytic anemia in dogs and cats

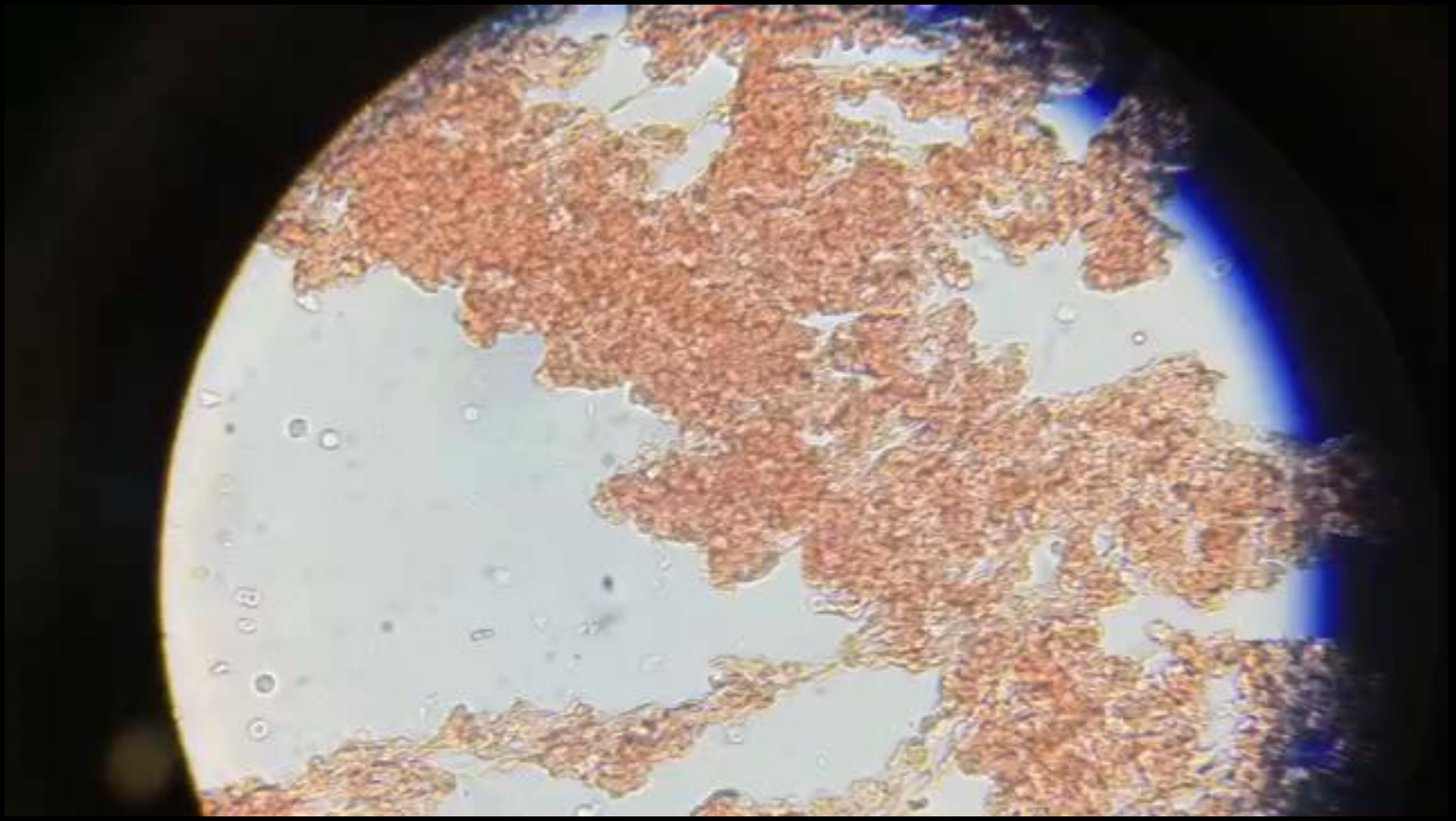

Received: 13 December 2018 | Accepted: 18 January 2019
DOI: 10.1111/jvim.15441

CONSENSUS STATEMENT

Journal of Veterinary Internal Medicine Open Access ACVIM American College of Veterinary Internal Medicine

ACVIM consensus statement on the diagnosis of immune-mediated hemolytic anemia in dogs and cats

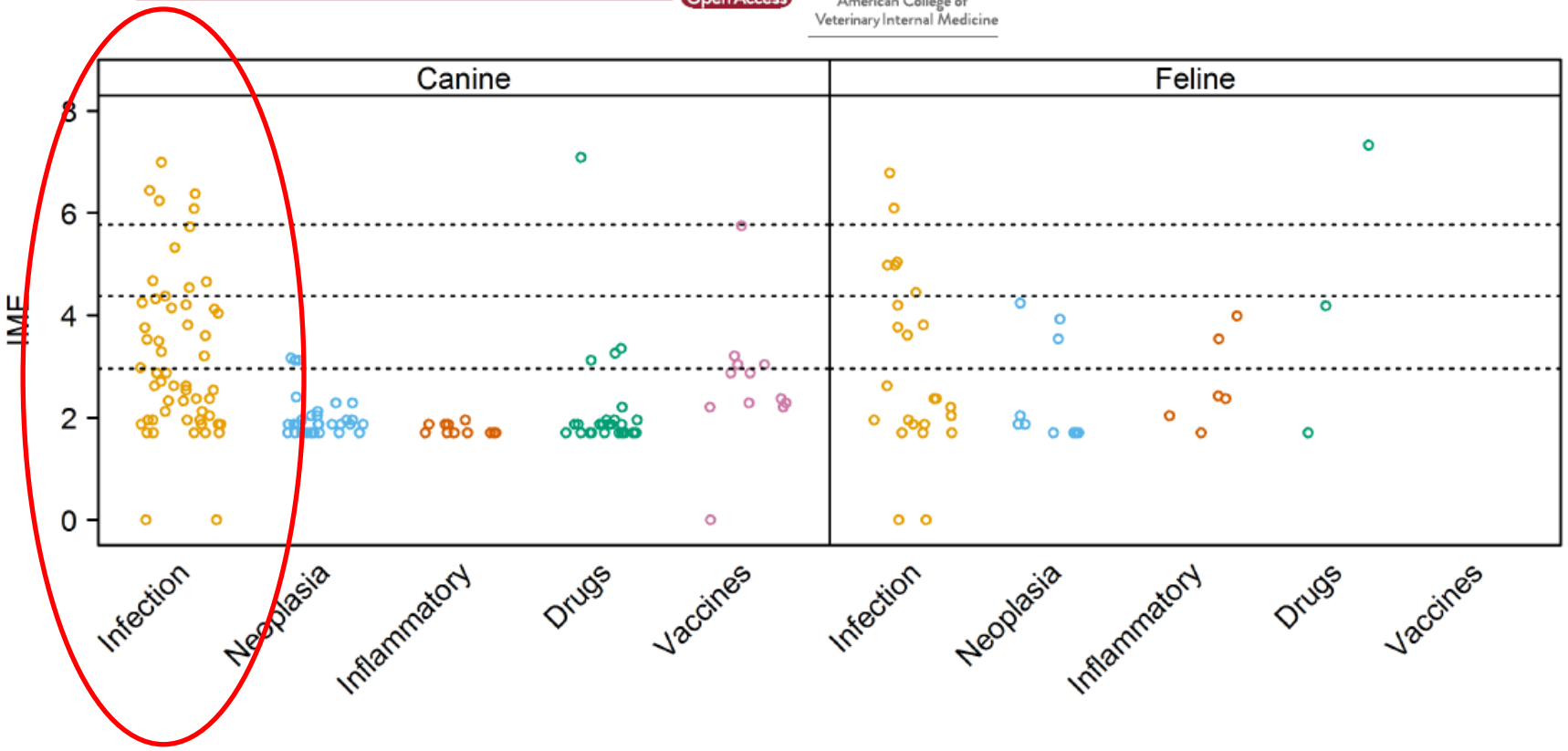

FIGURE 3 Integrated metric of evidence (IME) summary for all comorbidity categories. Horizontal dotted lines indicate the threshold IME values between negligible and low (2.95), low and intermediate (4.37), and intermediate and high (5.78) levels of evidence. Most IME values fell within the negligible and low zones of evidence, while a small number were 0, indicating evidence against that comorbidity inducing immune-mediated hemolytic

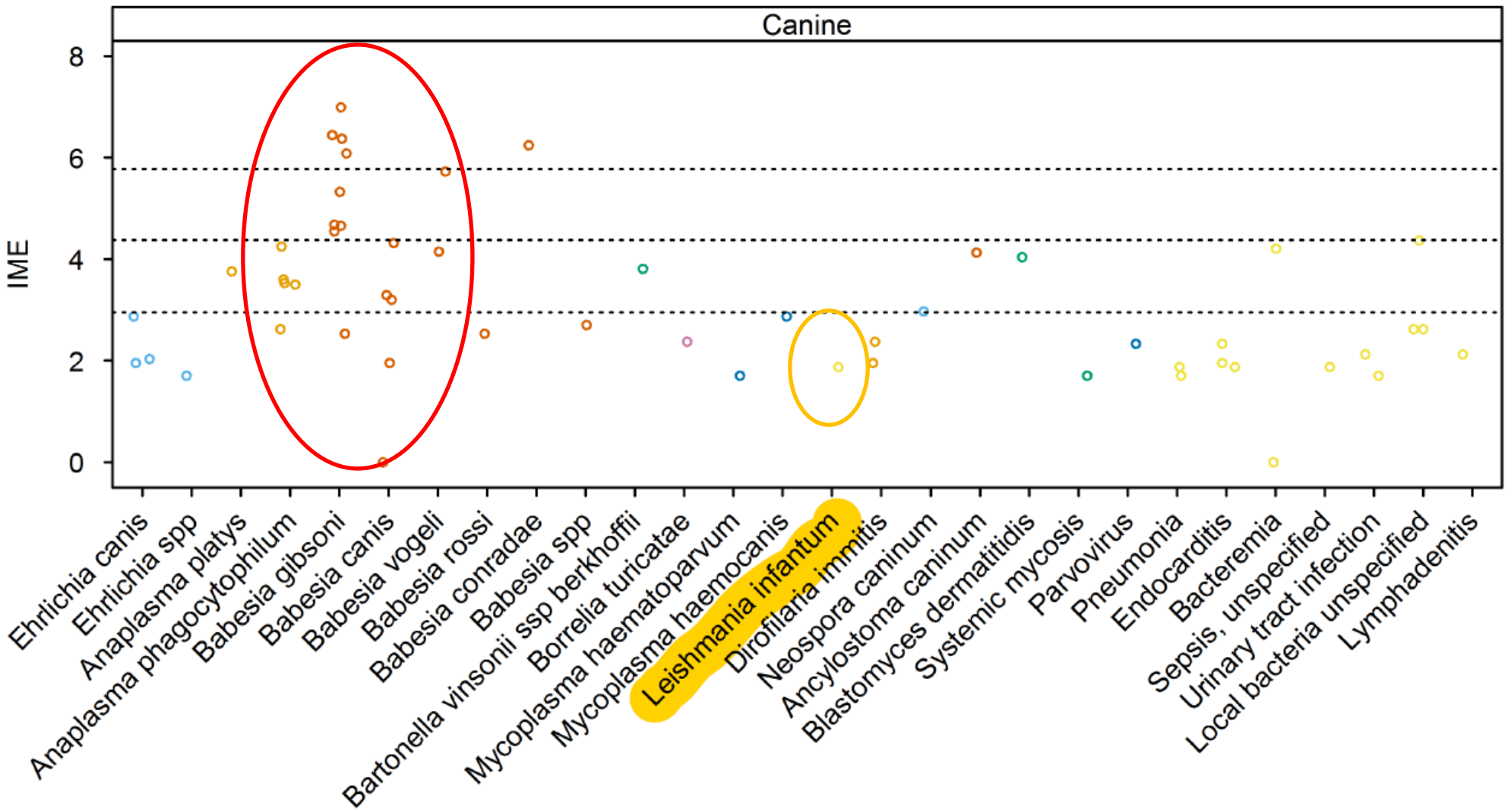

FIGURE 4 Integrated metric of evidence (IME) values for infectious agents and diseases in dogs. Horizontal dotted lines indicate the threshold IME values between negligible and low (2.95), low and intermediate (4.37), and intermediate and high (5.78) levels of evidence. spp, species (plural term)

Leishmaniosi e IMHA (anemia emolitica immunomediata)

ACVIM consensus statement on the diagnosis of immune-mediated hemolytic anemia in dogs and cats

Journal of Veterinary Internal Medicine
Open Access
ACVIM
American College of Veterinary Internal Medicine

Evidenza scientifica bassa / trascurabile !

ACVIM
American College of Veterinary Internal Medicine

→ Consigliato comunque testare i cani con IMHA in zone endemiche!

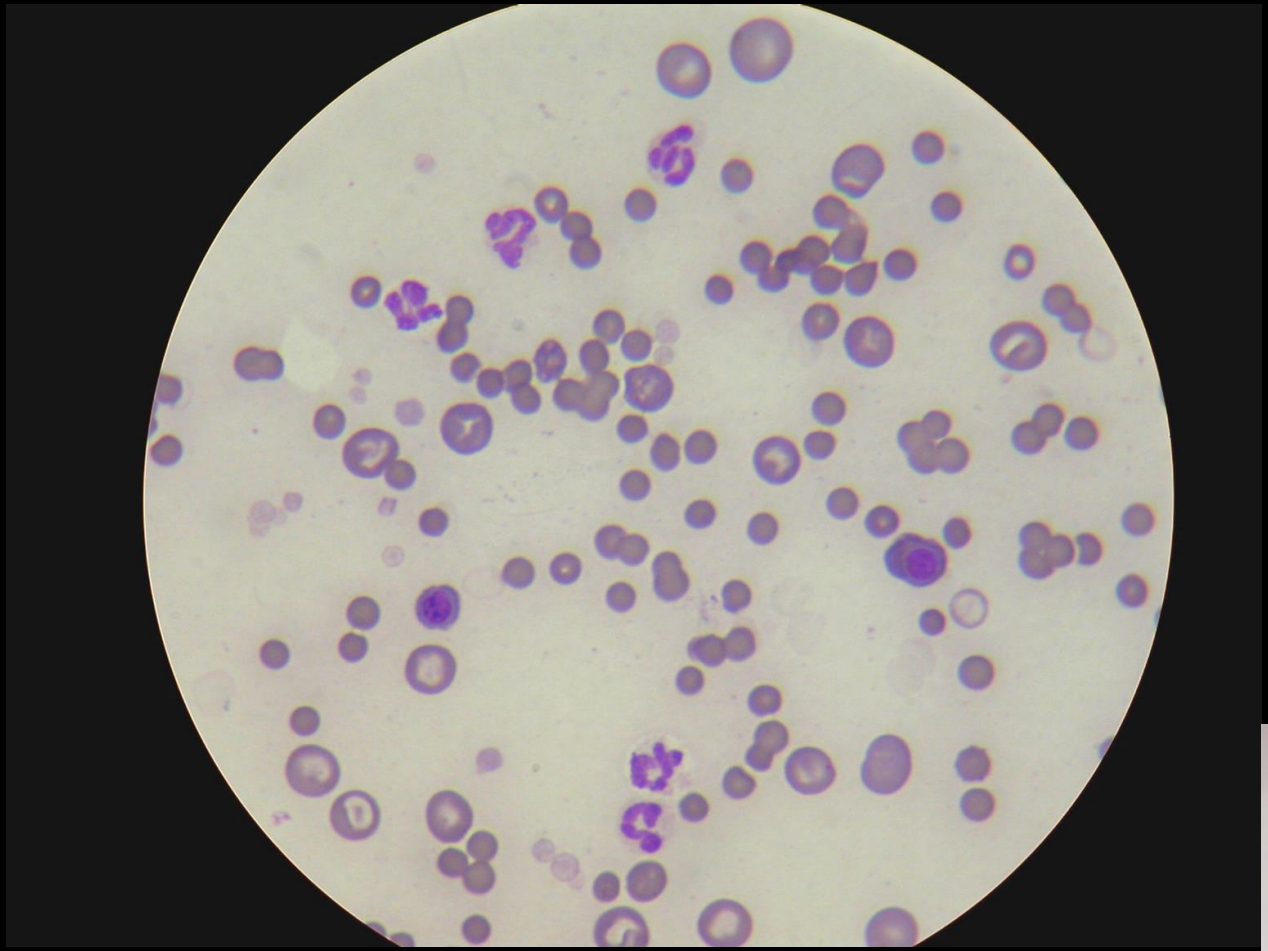

Daisy
Pit bull
FS
10 anni

Anemia
Sferocitosi
Iperbilirubinemia
Pigmenturia

IFI Leishmania + 1:1280
PCR midollo negativo

Campione di sangue EDTA Consegnato il 29/03/2016

ESAME	Valore	Unità	Intervallo di riferimento
Emoglobina	**4.0**	gr%	12 .. 18
Ematocrito	**13.5**	%	37.0 ... 55.0
Eritrociti	**1820000**	/mm³	5500000 ... 8500000
Piastrine	**103000**	/mm³	160000 ... 500000
Leucociti	**7550**	/mm³	6000 ... 17000
MCV	**74.2**	fL	60.0 ... 77.0
MPV	**22.1**	fL	6.6 ... 10.9
MCHC	**29.9**	gr%	32.0 ... 38.0
MCH	**22.2**	pgr	19.5 ... 24.5
RDW	**17.9**	%	13.0 ... 15.7
Reticolociti	**10.56**	%	0 ... 1.50
Reticolociti	**192400**	/mm³	0 ... 60000
Linfociti	**12.2**	%	
Monociti	**4.1**	%	
Neutrofili	**81.2**	%	
Eosinofili	**1.6**	%	
Basofili	**0.2**	%	0 ... 600
Linfociti	**920**	/mm³	1000 ... 4800
Monociti	**310**	/mm³	100 ... 1400
Neutrofili	**6130**	/mm³	3000 ... 12000
Eosinofili	**120**	/mm³	0 ... 750
Basofili	**20**	/mm³	0 ... 180
PCV	**14.0**	%	37.0 ... 55.0
Osservazioni	piastrine attivate+--		

Sferociti	presenti	+---
Anisocitosi	presente	+++-
Policromasia	presente	+---
Stima piastrinica	inadeguata	
Macropiastrine	presenti	+++-
Aggregati piastrinici	assenti	

Daisy
Pit bull
FS
10 anni

Anemia
Sferocitosi
Iperbilirubinemia
Pigmenturia

IFI Leishmania + 1:1280
PCR midollo negativo

Leishmaniosi e IMT (trombocitopenia immunomediata)

Leishmaniosi e IMT (trombocitopenia immunomediata)

Veterinary Immunology and Immunopathology 110 (2006) 331–337

Presence of anti-platelet IgM and IgG antibodies in dogs naturally infected by *Leishmania infantum*

G. Terrazzano [a], L. Cortese [b], D. Piantedosi [b], S. Zappacosta [a], A. Di Loria [b], D. Santoro [b], G. Ruggiero [a], P. Ciaramella [b,*]

63,3% (21/33) avevavo anticorpi anti-piastrine
- **9/33 trombocitopenici**
- 15/21 CanL sintomatica
- 21/21 PBIgM+
- 9/21 PBIgM& PBIgG +

Veterinary Record (2009) **164**, 778-782

Secondary immune-mediated thrombocytopenia in dogs naturally infected by *Leishmania infantum*

L. Cortese, M. Sica, D. Piantedosi, G. Ruggiero, M. E. Pero, G. Terrazzano, V. Mastellone, P. Ciaramella

72,7% (32/44) avevano anticorpi anti-piastrine
- **20/44 trombocitopenici**
- 20/32 PBIgM&PBIgG +
- 12/32 PBIgM +

The Veterinary Journal 188 (2011) 118–121

Prevalence of anti-platelet antibodies in dogs naturally co-infected by *Leishmania infantum* and *Ehrlichia canis*

Laura Cortese [a], Giuseppe Terrazzano [b,c], Diego Piantedosi [a,*], Michela Sica [b], Michele Prisco [a], Giuseppina Ruggiero [b], Paolo Ciaramella [a]

Positivi a anticorpi anti-piastrine:
- 80% (8/10) co-infetti *L.infantum e E. canis*
- **50% (5/10) *L.infantum***
- 60% (6/10) *E. canis*

Leishmaniosi e IMT (trombocitopenia immunomediata)

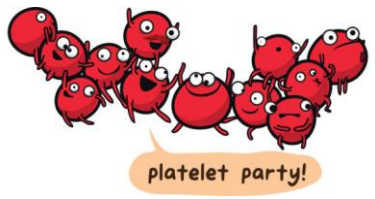

- Trombocitopenia non così frequente
- Elevate positività anticorpi anti-PLT anche in pazienti non trombocitopenici

→ correlazione tra trombocitopenia & anticorpi anti-PLT ?

altri meccanismi patogenetici?

- Soggetti con co-infezioni maggiore frequenza di anticorpi anti-PLT, ma non più trombocipenici

→ Alterata funzionalità piastrinica?

Leishmaniosi e Citopenie

Meccanismi immunomediati sono possibili

+ frequenti → meccanismi diversi dalla distruzione immunomediata :

coinvolgimento diretto del midollo osseo	➢ piastrinopenia, anemia, leucopenia
flogosi	➢ anemia (leucocitosi)
alterazioni emostatiche	➢ piastrinopenia, anemia
perdita	➢ anemia
CKD	➢ anemia

˝Cortisone˝ sì o no ?
Dosaggio ?
Altre terapie immunosoppressive ?

Leishmaniosi: alterazioni clinicopatologiche

	Tipiche	Frequenti	Occasionali
CBC - Leucociti		neutrofilia	linfopenia linfocitosi eosinofilia
CBC - Eritrociti	anemia normocitica-normocromica non rigenerativa		test di Coombs +
CBC - Piastrine			trombocitopenia → co-infezioni
Emostasi		↓antitrombina	↑ PT e aPTT ipercoagulabilità (TEG)
Chimica clinica	iperazotemia ↑PT, ↓ albumine,↓ A/G		danno altri tessuti ?
Elettroforesi	gammopatia policlonale	gammopatia oligoclonale	gammopatia mono- o biclonale
Proteine di fase acuta	↑ CRP e APPs ↓ TIBC		
Analisi urinaria	↑ UPC, ↓ USG		

Paltrinieri et al

Vet Clin Pathol 45/4 (2016) 552–578 ©2016 American Society for Veterinary Clinical Pathology

Iperprotidemia

- Emoconcentrazione (↑ albumine, a/g =)
- Aumentata sintesi proteica

da Stockham e Scott, Fundametals of Vet. Clin. Path., 2008

Aumentata sintesi proteica

INFIAMMAZIONE

infezioni (croniche): batteriche, virali, funghi, parassiti

Leishmaniosi, Ehrlichiosi
altre malattie trasmesse da zecche

malattie “non infettive”: neoplasie, immunomediate (LES)

NEOPLASIA linfoide o plasmocellulare

Plasmacellule → plasmocitoma, mieloma multiplo

Linfociti → linfomi, leucemie linfocitiche

da Stockham e Scott, Fundametals of Vet. Clin. Path., 2008

Iperprotidemia e Ipergammaglobulinemia nel cane

Patologie infiammatorie/infettive (Ehrlichiosi, Anaplasmosi, ***Leishmaniosi***, Borreliosi, piometra, etc)

Patologie immunomediate

Neoplasie linfociti B e delle plasmacellule

da Stockham e Scott, Fundametals of Vet. Clin. Path., 2008

Approccio alla Proteinuria

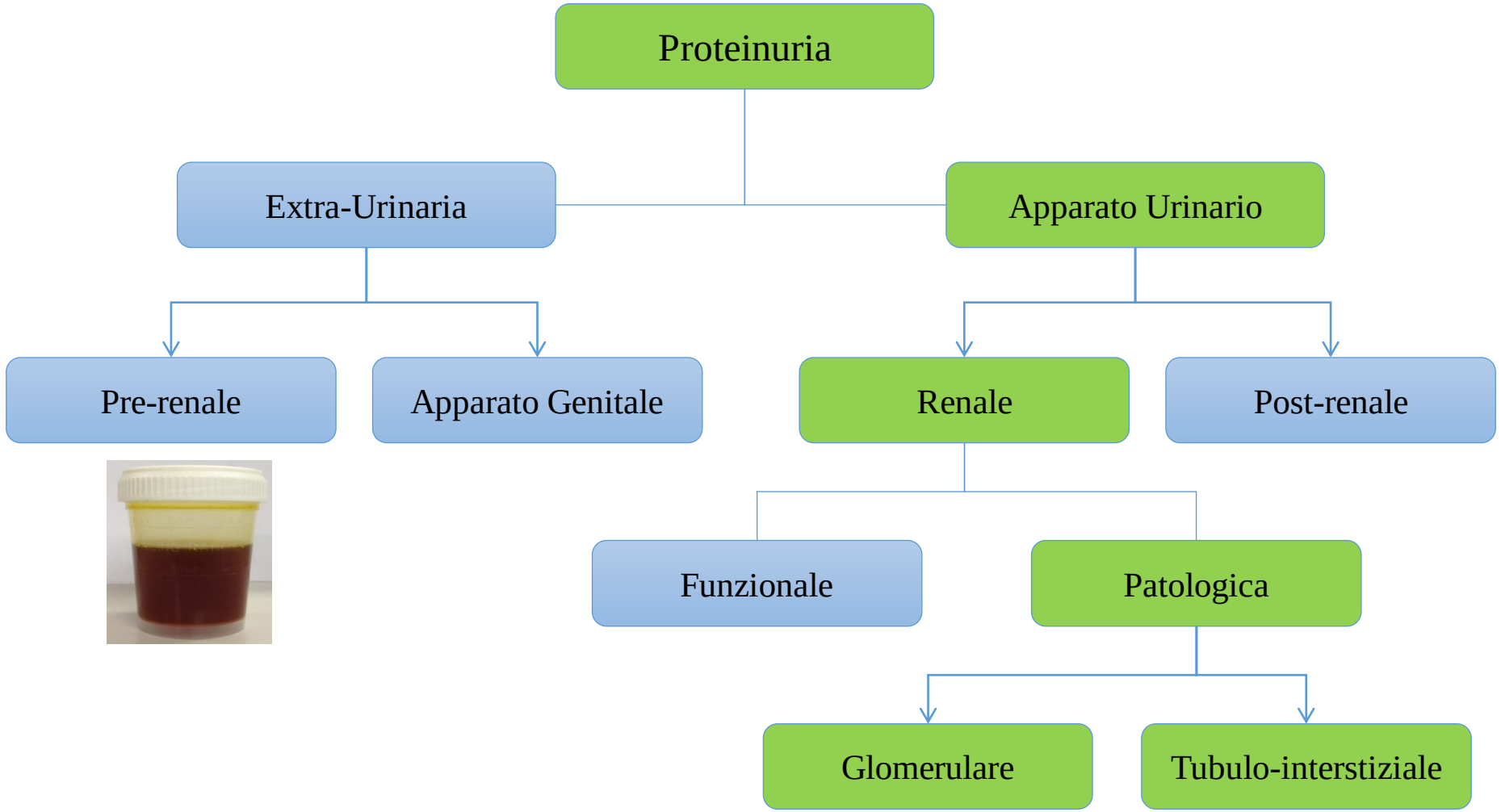

Segev G, 2010 – ACVIM consensus statemet 2005

IRIS International Renal Interest Society

Diagnosi, Stadiazione e Trattamento della Malattia Renale Cronica

PU/CU

Sottostadiazione basata su proteinuria

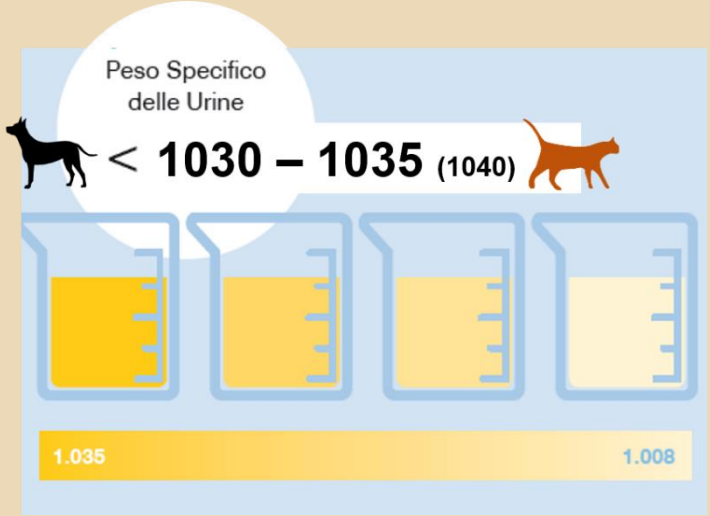

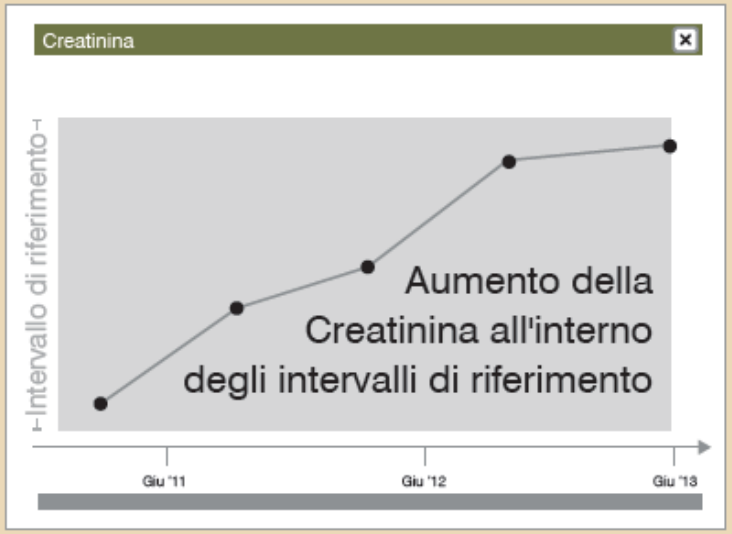

Aumento persistente
dell'SDMA >14 μg/dL

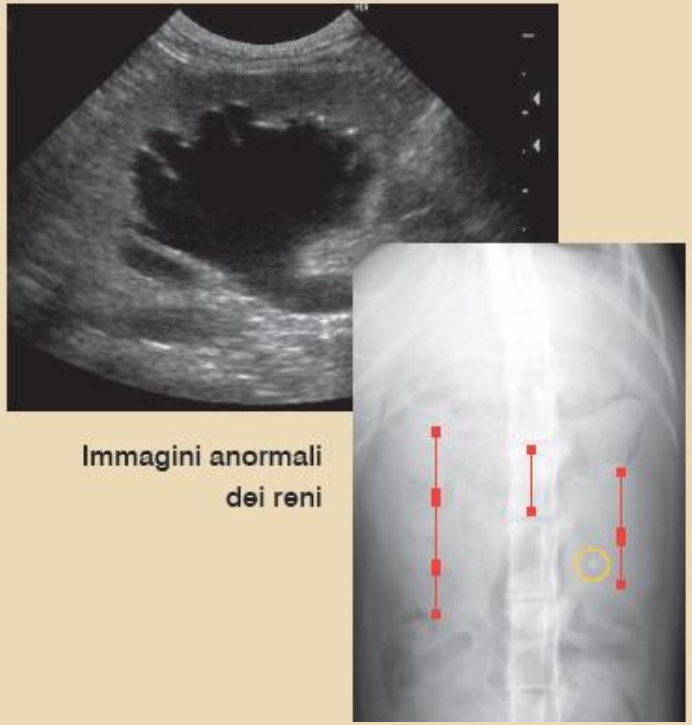

Immagini anormali
dei reni

diagnosi
precoce

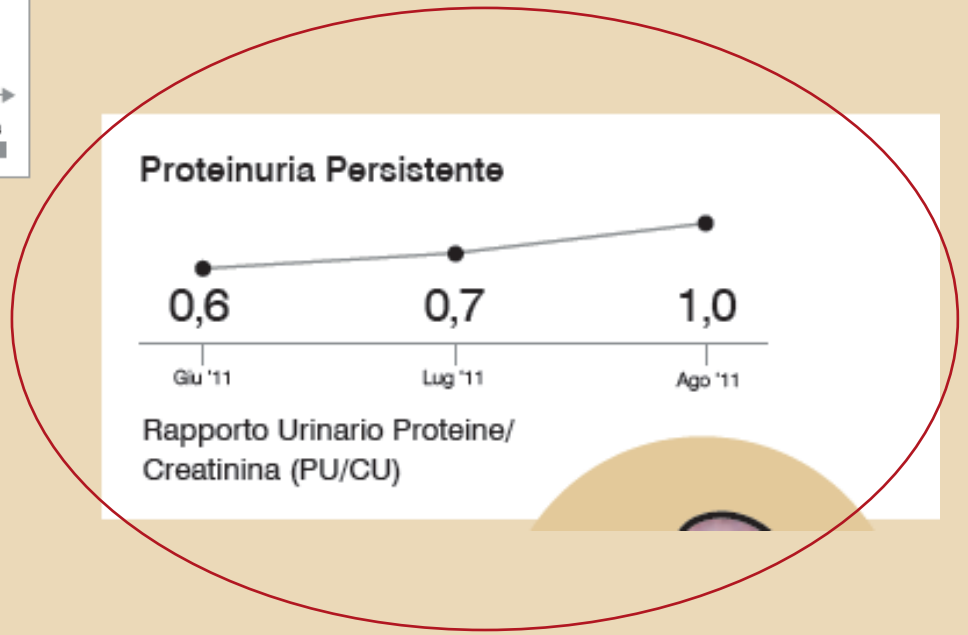

Biopsia renale

Ringraziamenti:

Sofia Segatore

Roberta Troìa
Chiara Grisetti
Erika Monari
Kateryna Vasylyeva
Silvia Zamagni
Alessandro Tirolo
Linda Perissinotto

Tutti i colleghi della UO di Nefrologia e Urologia

f.dondi@unibo.it

Perla - *Segnalamento*

Cane

Meticcio

Femmina sterilizzata

4 anni

25 kg

Motivo della visita:
zoppia/anoressia

Perla - *Anamnesi*

Cane
Meticcio
Femmina sterilizzata
4 anni
25 kg

Adottata da un canile di Napoli (1 anno prima)

Asportazione di un plasmacitoma cutaneo localizzato nel carpo destro (3 mesi prima)

Nessun approfondimento diagnostico prima/dopo l’esame istologico

Regolarmente vaccinata e trattata per endo-ectoparassiti

Perla - *Anamnesi*

- zoppia ?
- ultimi 15-20 giorni: depressione del sensorio, PU/PD ?
- ultimi 7 giorni: disoressia/anoressia
- dimagrimento
- esami eseguiti da un collega 48 h prima della visita rilevano iperazotemia

```
**********
11/10/17        18:36
ID# 0002
**********
 MULTI:PANEL-U
BUN          37 mg/dl
Glu          90 mg/dl
ALP    UNDER <    50
T-Pro    10.9 g/dl
GPT    UNDER <    10
Cre         4.7 mg/dl
----------------------
```

Perla - *Esame fisico diretto*

- BCS 4/9; MCS 1

- depressione del sensorio

-scolo nasale bilaterale (siero-ematico)

- **linfoadenomegalia generealizzata**

- normotermica (39.0°C)

- **splenomegalia**

- **tumefazione/dolore articolare arti anteriori**

Perla - *Misurazione pressione arteriosa*

P.A. 200 mm-Hg

ipertensione arteriosa grave

Perla - *Problem list*

Zoppia e tumefazione articolare

Linfoadenomegalia - Splenomegalia

Ipertensione

Depressione del sensorio

Calo dell’appetito e dimagrimento

Iperazotemia ?

Perla - *Protocollo diagnostico*

- esame emocromocitometrico
- profilo chimico + elettroforesi
- analisi delle urine
- a.a. linfonodale
- artrocentesi e citologia del liquido articolare

- eco addome e Rx torace
- Rx arti

ESAME	Valore	Un.mis.	Range di riferimento
Emoglobina	14.8	gr%	12 .. 18
Ematocrito	46.1	%	37.0 ... 55.0
Eritrociti	7270000	/mm^3	5500000 ... 8500000
Piastrine	208000	/mm^3	160000 ... 500000
Leucociti	4510	/mm^3	6000 ... 17000
MCV	63.4	fL	60.0 ... 77.0
MPV	16.6	fL	6.6 ... 10.9
MCHC	32.0	gr%	32.0 ... 38.0
MCH	20.3	pgr	19.5 ... 24.5
RDW	15.1	%	13.0 ... 15.7
Reticolociti	1.45	%	0 ... 1.50
Reticolociti	105400	/mm^3	0 ... 60000
Linfociti	26.4	%	
Monociti	5.5	%	
Neutrofili	63.2	%	
Eosinofili	4.2	%	
Basofili	0.2	%	0 ... 600
Linfociti	1190	/mm^3	1000 ... 4800
Monociti	250	/mm^3	100 ... 1400
Neutrofili	2850	/mm^3	3000 ... 12000
Eosinofili	190	/mm^3	0 ... 750
Basofili	10	/mm^3	0 ... 180

Cellule bersaglio	presenti	+---
Anisocitosi	presente	+---
Stima piastrinica	adeguata	
Macropiastrine	presenti	+---
Aggregati piastrinici	assenti	

ESAME	Valore	Un.mis.	Range di riferimento
AST	33	U/l	20 ... 42
ALT	12	U/l	20 ... 55
Fosfatasi alcalina	49	U/l	42 ... 180
Creatinina	5.06	mg/dl	0.65 ... 1.35
Urea	133.91	mg/dl	18 ... 55
Glucosio	77	mg/dl	70 ... 125
Bilirubina Totale	0.18	mg/dl	0.07 ... 0.34
Colesterolo Totale	96	mg/dl	140 ... 350
GGT	0.1	U/l	0 ... 5.8
Proteine totali	14.38	g/dl	5.60 ... 7.90
Albumina	2.11	g/dl	2.80 ... 3.70
Albumina/Globuline	0.17		0.60 ... 1.30
Calcio	10.3	mg/dl	9.0 ... 11.8
Calcio corretto	11.7	mg/dl	8.0 ... 12.0
Fosforo	6.20	mg/dl	2.6 ... 4.90
Sodio	140	mEq/l	143 ... 154
Potassio	3.9	mEq/l	3.9 ... 5.3
Cloro	109	mEq/l	108.0 ... 118.0
C-Reac-Prot	3.13	mg/dl	0 ... 0.5

ESAME URINE

Campione di urina

Colore	Giallo paglierino
Trasparenza	Limpida

ESAME	Valore	Valori normali
pH	5.50	
Peso Specifico	1010	**> 1030**
Proteine	negativo	**Assenti**
Emoglobina	negativo	**Assente**
Leucociti	negativo	**Assenti**
Glucosio	normale	**Assente**
Corpi chetonici	negativo	**Assenti**
Bilirubina	negativo	**Assente**

Altro nel Sedimento nulla da evidenziare

Proteinuria ?

Perla - *Ecografia addominale*

Reni aumentati di volume

Lieve pielectasia

Milza omogenea, ripiegata, aumentata di volume

1200000335
Serv.Ecografia Vet. UNIBO C8-5/ADDOME cane
M3
Rene sx
26
36
43
50
59
63
64
63
0
1
2
3
4
5
6
7

1200000335
Serv.Ecografia Vet. UNIBO C8-5/ADDOME cane
M3
Milza
P
26
36
43
50
59
63
64
63
0
1
2
3
4
5
6
X

Perla - *Rx torace*

- nei limiti della norma

Perla - *ulteriori indagini*

Elettroforesi sierica

Frazioni	%	Int. rif. %	g/dl	Int. rif. g/dl
Albumina	14,8		2,1	2.80 … 3.70
Alfa 1	4,1		0,6	0.1 … 0.35
Alfa 2	8,6		1,2	0.40 … 0.95
Beta 1	5,2		0,7	0.63 …1.05
Beta 2	19,8		2,8	0.35 … 0.80
Gamma	47,5		6,8	0.42 … 0.78

A/G **0,17** (Rif.: 1,10 - 2,40) Proteine Totali : **14,38** g/dl

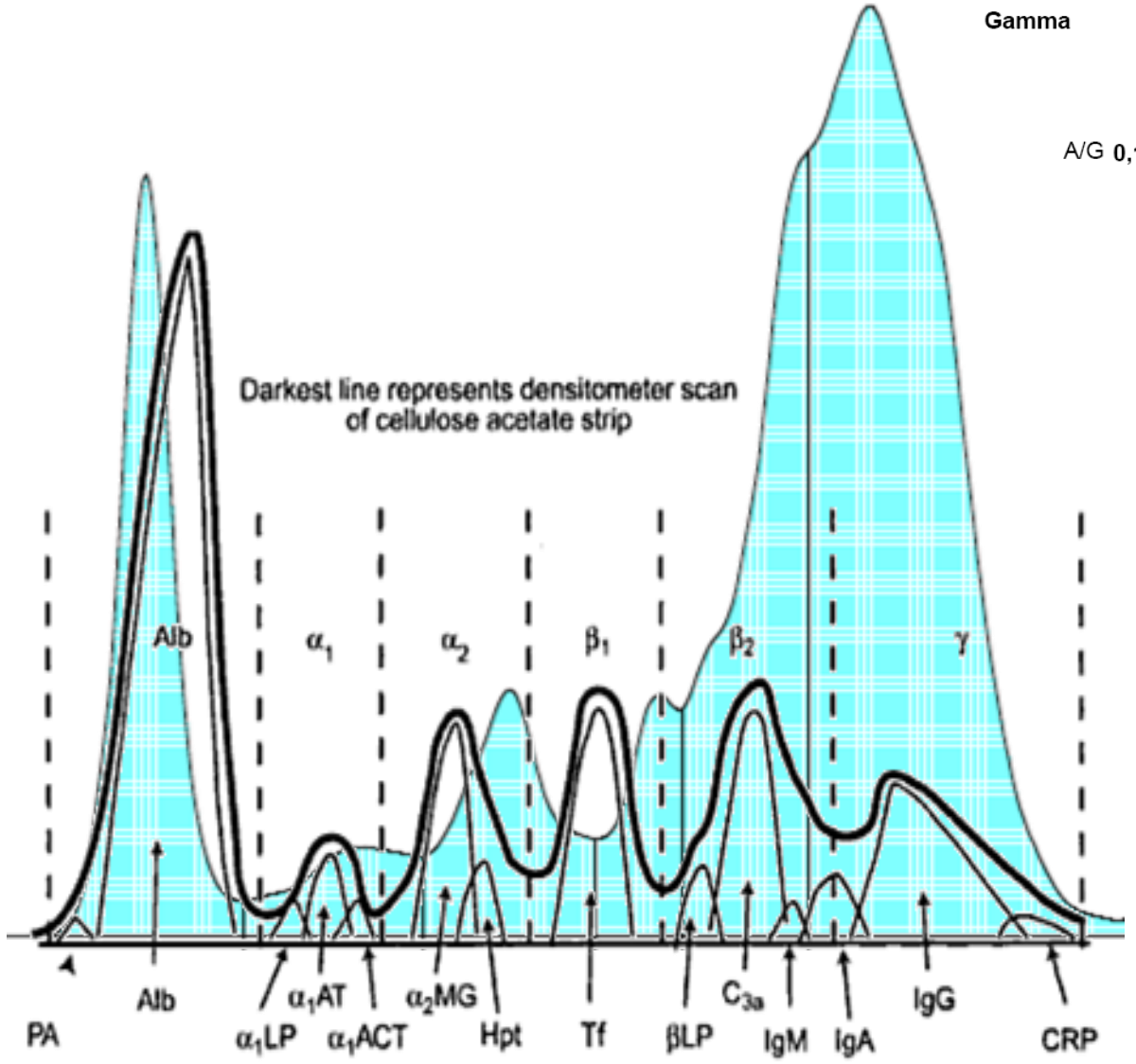

da Stockham e Scott, Fundametals of Vet. Clin. Path., 2008

Iperprotidemia

- Emoconcentrazione (↑ albumine, a/g =)
- Aumentata sintesi proteica

da Stockham e Scott, Fundametals of Vet. Clin. Path., 2008

Aumentata sintesi proteica

INFIAMMAZIONE

infezioni (croniche): batteriche, virali, funghi, parassiti

Leishmaniosi, Ehrlichiosi
altre malattie trasmesse da zecche

malattie “non infettive”: neoplasie, immunomediate (LES)

NEOPLASIA linfoide o plasmocellulare

Plasmacellule → plasmocitoma, mieloma multiplo

Linfociti → linfomi, leucemie linfocitiche

da Stockham e Scott, Fundametals of Vet. Clin. Path., 2008

Aumento della sintesi proteica

L'infiammazione è la causa più comune di iperprotidemia

INFIAMMAZIONE → AUMENTA la SINTESI di GLOBULINE (↓Alb)

SINTESI RAPIDA di PROTEINE di FASE ACUTA iperprotidemia lieve/moderata

ore - giorni → alfa e beta-globuline → **+ 1 - 2 g/dl**

SINTESI "TARDIVA" di "DELAYED RESPONSE PROTEINS" iperprotidemia
immunoglobuline e complemento moderata/grave

1-3 settimane → beta e gamma-globuline → **fino a + 4 g/dl e oltre**

da Stockham e Scott, Fundametals of Vet. Clin. Path., 2008

Iperprotidemia e Ipergammaglobulinemia nel cane

Patologie infiammatorie/infettive (Ehrlichiosi, Anaplasmosi, **Leishmaniosi**, Borreliosi, piometra, etc)

Patologie immunomediate

Neoplasie linfociti B e delle plasmacellule

da Stockham e Scott, Fundametals of Vet. Clin. Path., 2008

Ulteriori indagini:

Cosa fareste ?

- sierodiagnosi IFI:

Leishmania spp.

Ehrlichia canis

Anaplasma phagocitophilum

…

Altro ?

- esame citologico del midollo osseo e della milza

MIDOLLO OSSEO

- conta plasmacellulare 5%, assenza di infiltrati plasmacellulari atipici, mielogramma WRI

- assenza di microrganismi riferibili a *Leishmania spp.*

- assenza di inclusioni citoplasmatiche riferibili a *Ehrlichia canis* o *Anaplasma phagocytophilum*

Milza

- iperplasia associata a mielopoiesi extramidollare

- assenza di infiltrati plasmacellulari atipici

- assenza di microrganismi riferibili a *Leishmania* spp.

IMMUNOFLUORESCENZA INDIRETTA

Leishmania spp. - IFI	Positivo	**Titolo:**1:320
Ehrlichia canis - IFI	Positivo IgG	**IgG:**1:1280
Ehrlichia gran. IFI	Positivo IgG	**IgG:**1:1280

?



Ehrlichia o Anaplasma?



Ehrlichia canis - IFI	Positivo IgG	IgG:1:1280
Ehrlichia gran. IFI	Positivo IgG	IgG:1:1280

- PCR

- positiva per *Ehrlichia canis*

e se fosse stata negativa ?

ESAME URINE

Campione di urina

Colore	Giallo paglierino
Trasparenza	Limpida

ESAME	Valore	Valori normali
pH	5.50	
Peso Specifico	1010	**> 1030**
Proteine	negativo	**Assenti**
Emoglobina	negativo	**Assente**
Leucociti	negativo	**Assenti**
Glucosio	normale	**Assente**
Corpi chetonici	negativo	**Assenti**
Bilirubina	negativo	**Assente**

Altro nel Sedimento nulla da evidenziare

Proteinuria ?

ESAME URINE

Campione di urina

Colore	Giallo paglierino		
Trasparenza	Limpida		
ESAME	**Valore**		**Valori normali**
pH	5.50		
Peso Specifico	1010		**> 1030**
Proteine	negativo		**Assenti**
Emoglobina	negativo		**Assente**
Leucociti	negativo		**Assenti**
Glucosio	normale		**Assente**
Corpi chetonici	negativo		**Assenti**
Bilirubina	negativo		**Assente**
P.Tot.	44.6	mg/dl	
P.Tot/Crea urinarie	0.6		0.0 ... 0.4
Creatinina urinaria	75.65	mg/dl	
albumina -immunologico-	12.85	mg/dl	0 ... 3
Esame del Sedimento:			
Altro nel Sedimento	nulla da evidenziare		

UPC 0,6	R.I. < 0,4
UAC 0,17	R.I. < 0,02
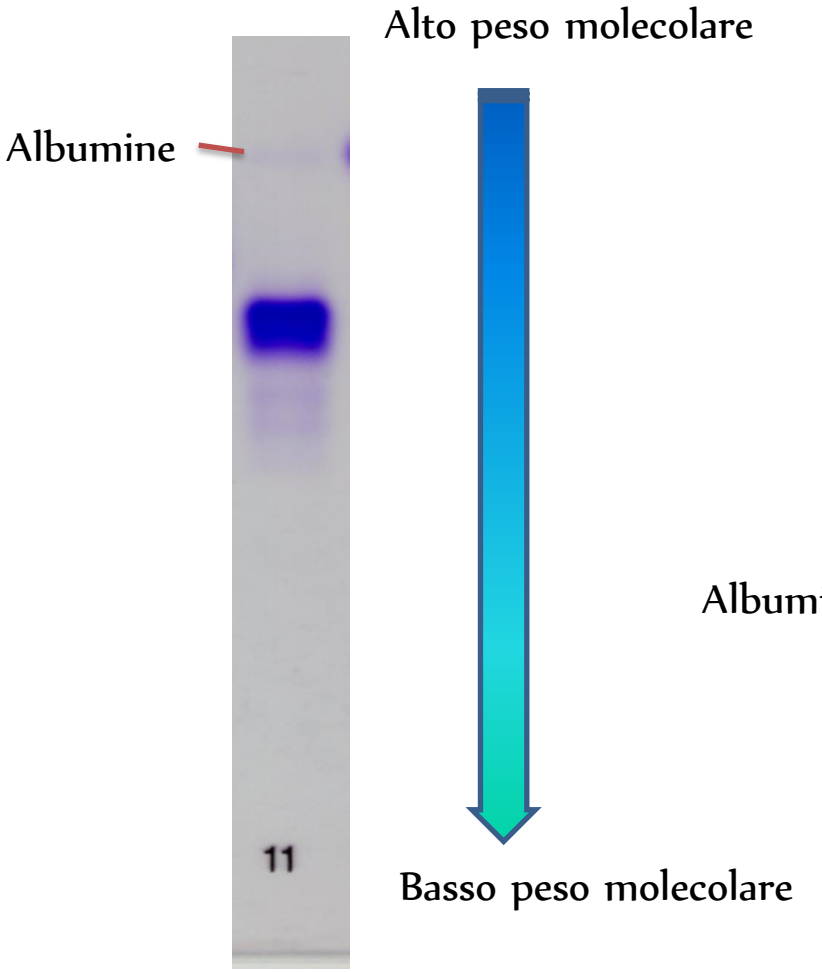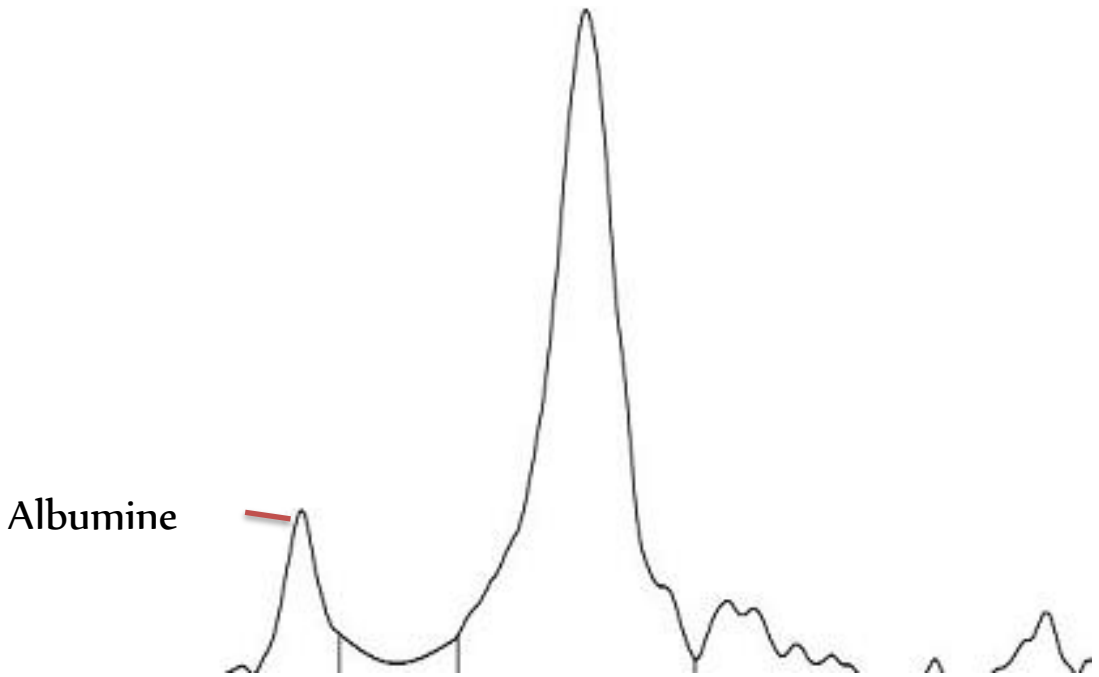
Elettroforesi proteine urinarie (gel di agarosio HRE)